

## Comparative evaluation of interface between two bonding systems and crown and root dentine using optical microscopy

F.Dabsie, H.El yaâgoubi, G.Grégoire

[Biomaterials Laboratory](#), Faculty of Odontology, University of Toulouse III, Toulouse, France

**INTRODUCTION:** Adhesion to dental tissues is achieved by using bonding systems which lead to the formation of a hybrid layer, a mixture of adhesive polymers and the demineralised tissues of the tooth. The dentin morphology is one of the factors that influence the effectiveness of the seals obtained with bonding systems. The aim of this study was to compare, by optical microscopy, the morphology of the hybrid layer produced in crown and root dentin after application of two bonding systems, a phosphoric acid etch-and-rinse system and a self etching system.

**METHODS:** Twelve healthy molars extracted because of developmental pathologies were used. A 2-mm-thick dentin disk was cut from each tooth and randomly assigned to one of two groups: Group I to receive Excite\* one-bottle system preceded by prior etching with phosphoric acid, which is a photopolymerizable product having an ethanol-based solvent; or Group II to receive AdheSE\* self-etch, which is photopolymerizable and has a water-based primer applied in two steps. Twelve single-rooted human teeth extracted for periodontal reasons were prepared endodontically with Hero system 6-4-2, and randomly assigned to one of two groups: Group I to receive Excite DSC\* simplified dual system preceded by prior etching with phosphoric acid, or Group II to receive AdheSE DC\*, a dual self-etch system applied in two steps with an endodontic microbrush.

<sup>1</sup>The specimens were prepared for optical microscopy and stained. To standardize the observations, microphotographs at 320x magnification were taken systematically.

\*Ivoclar Vivadent, Schaan, Leichtenstein

**RESULTS:** The stain used coloured the dentin yellow and the resin bright pink.

The interface observed in groups I and III showed a regular hybrid layer with a thickness sometimes reaching 10µm, and short, v-shaped tags (14 to 28µm). These tags were conical and sealed the upper parts of the tubuli. The interface observed in groups II and IV showed a regular hybrid layer varying in thickness (1.5 to 3 µm). Tags were numerous, long and fine. Tag lengths were at least 21µm and sometimes reached 98µm, their length depending on the location in the canal. They ensured intimate contact with the dentin walls.

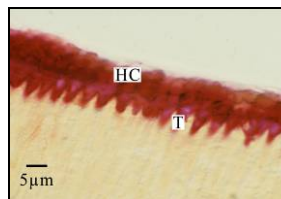


Fig.1. Hybrid layer obtained with Excite applied to crown dentin (x320)

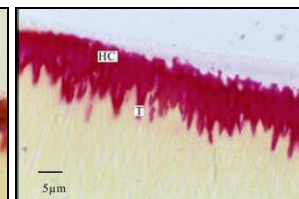


Fig.2. Hybrid layer obtained with Excite DSC applied to root dentin (x320)

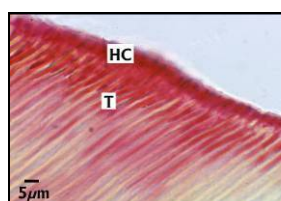


Fig. 3. Hybrid layer obtained with AdheSE applied to crown dentin (x320)

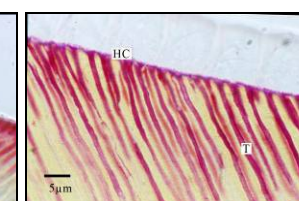


Fig.4. Hybrid layer obtained with AdheSE DC applied to root dentin (x320)

**DISCUSSION AND CONCLUSION:** The hybrid layer obtained with the self-etch system was thinner than that obtained with a phosphoric etch preceding adhesive application, and the results of our study are in agreement with the literature.<sup>2</sup> The difference may be explained by the fact that, with self-etch systems, the presence of the dentin smear layer will result in a smaller depth of dentine infiltration. The regular morphology of the hybrid layer obtained with the self-etch systems is due to the fact that the demineralization and infiltration take place simultaneously.

The results show a good contact between the tags and the walls of the tubuli with both adhesive systems, which is favourable for good sealing. Our results show that there are no differences in the morphology of the hybrid layer produced in the crown and the root after application of two bonding systems. But the tag density decreases from the crown third to the root third.<sup>3</sup>

**REFERENCES:** <sup>1</sup>Wang Y, Journal of Dentistry, 2004;(32),567-5792;<sup>2</sup>Wang Y, European Journal of OralScience,2004;112:2932993;<sup>3</sup>Grégoire, Operative Dentistry,2005;30(4):481-914;<sup>4</sup>Grégoire G, Journal of Prosthodontic Dentistry ,2002;87(6): 633-41-5;<sup>5</sup> Itou K.,American Journal of Dentistry, 2003;16(5):335-339;<sup>6</sup>Ferrari M. American Journal of Dentistry, 2000;13(5):255-260;<sup>7</sup>Bitter K., International Endodontic Journal, 2004; 3,840-848