

INVESTIGATING THE ROLE OF COLLAGEN IN PERIPHERAL NERVE BIOMECHANICS

S. Mason¹ J. Harle² J.B. Phillips¹

¹Department of Life Sciences, The Open University, Milton Keynes.

²Department of Physics and Astronomy, The Open University, Milton Keynes.

INTRODUCTION Peripheral nerves bend and stretch around joints during normal movement. Previous studies have demonstrated that the joint and non-joint areas of rat peripheral nerve are biomechanically diverse, with areas of nerve at joints more compliant than those areas at non-joint sites¹. The rat sciatic nerve consists of bundles of axons surrounded by layers of perineurium and epineurium. Collagen is the most abundant of the structural proteins in these layers². The aim of this study was to quantify and compare the collagen in the joint and non-joint areas of rat sciatic nerve using electron microscopy and histological techniques.

METHODS Joint and non-joint regions of rat sciatic nerve were resected and prepared for microscopic examination. Digital image analyses were performed on electron and light micrographs to quantify and evaluate the collagen in each nerve section.

RESULTS The collagen ultrastructure of the connective tissue layers of the rat sciatic nerve was revealed by TEM (*Fig 1*). Martius/Scarlet/Blue (MSB) staining of epi- and perineurial collagen (*Fig 2*) showed no significant difference between joint and non-joint regions of rat sciatic nerve (*Fig 3*).

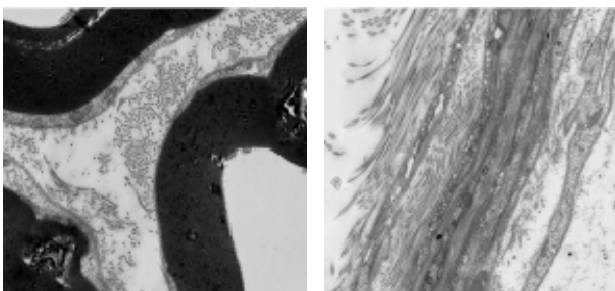


Fig 1: Transmission electron micrographs showing distinct collagen fibrils in endoneurium (left; x6000) and epi- and perineurium (right; x5000).

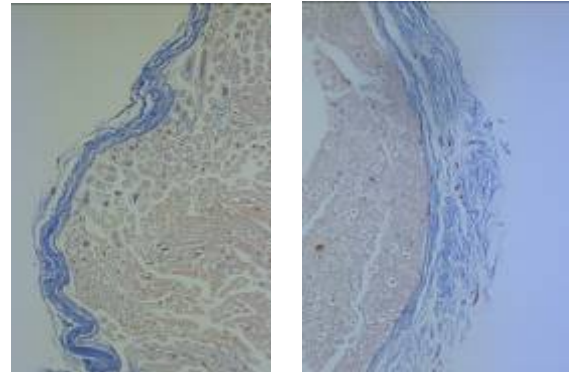


Fig 2: MSB staining showing blue collagen fibrils in the epi- and perineurium of a joint area (left) and a non-joint area of rat sciatic nerve (right).

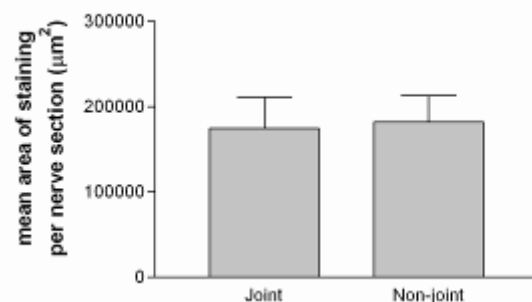


Fig 3: Mean area of MSB collagen staining, joint and non-joint areas of rat sciatic nerve.

DISCUSSION & CONCLUSIONS There was no significant difference in the quantity of collagen in joint and non-joint areas of sciatic nerve. This implies that the mechanical heterogeneity of peripheral nerves is likely to be due either to other structural proteins, or ultrastructural features of the collagen architecture.

REFERENCES 1. Phillips JB, Smit X, De Zoysa N, Afoke A, Brown RA. (2004) *J. Physiol.*, 557(3):879-87.
2. Sunderland, S. (1978) *Nerves and nerve injuries*. 2nd ed. Churchill Livingstone, Edinburgh.