

BMP-7 and Mesenchymal stem cells promote allograft integration

[M. Pierini](#)¹, [C. Di Bella](#)¹, [M. Fini](#)², [B. Dozza](#)¹, [T. Frisoni](#)¹, [E. Lucarelli](#)¹, [F. Salamanna](#)², [M. Sartori](#)², [D. Donati](#)¹

¹ Bone Regeneration Laboratory, [Rizzoli Orthopaedic Institute](#), Bologna, Italy

² Laboratory of pre-clinical studies, Rizzoli Orthopaedic Institute, Bologna, Italy

INTRODUCTION: The effectiveness of massive bone allografts depends on the healing time and the type of graft host integration. Numerous studies in animal models demonstrated the increased ability in bone-allograft integration when recombinant human Bone Morphogenetic Proteins (rh-BMPs) is added to the site of interest (1), (2). Mesenchymal Stem Cells (MSC) represent an important building block for regenerative medicine and tissue engineering. We previously demonstrated that MSC delivered in a collagen and PRP-based scaffold were able to improve allograft integration in a sheep model (3). The aim of the current study was to investigate whether the association of BMP-7 and MSC improved allograft integration in sheep model.

METHODS: Twenty sheep were randomly assigned to four groups of five animals each. Group I allograft alone, II MSC, III BMP-7, IV BMP-7 + MSC. Autologous MSC isolated from the bone marrow were expanded ex-vivo. A critical defect 3 cm wide was made in the middle part of the metatarsal bone. The defect was replaced with a sterile allograft. Four × 10⁶ MSC were mixed with sterile rat tail-derived collagen (group II), or BMP 7 (group IV), and applied inside and around the allograft. Animals were radiographed in AP view projection. Osteotomy lines were sectioned in a frontal plane passing through the polar line including part (10 mm) of the grafted bone (osteotomy sides) leaving about 2 cm of the graft which was cut in a transverse plane (central side). All specimens were embedded in methylmethacrylate to evaluate the percentage of new bone. Statistical analysis was performed with the Mann-Witney test calculated with the Monte Carlo method for small groups. Significance was established as p < 0.05.

RESULTS: In group III, as well as in IV, the osteotomy lines were almost not detectable already at 2 months after surgery. On the other hand, in Group I and II the healing was slower and not complete even after 4 months. Histology showed that in group I the integration of the graft

was mainly by external callus formation with limited new bone within the graft. In group I and II the new bone formation occurred mainly starting from the periosteal callus. In group III, instead, histology showed that the remodeling processes were predominant inside the graft. In this group the graft appeared to be almost completely reabsorbed after 4 months. On the other hand, in group IV the graft was not reabsorbed, the remodeling processes were coupled with a good amount of new bone apposition and a fair amount of newly formed bone within its structure (Fig.1). Histomorphometric measurements evidenced that the percentage of new bone formation within the graft was clearly higher in the group IV.

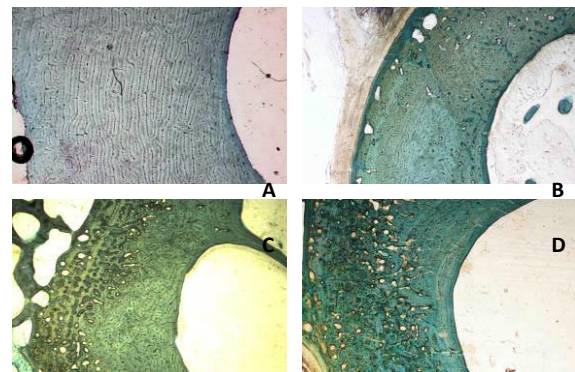


Fig. 1: Trichromic Masson staining of histological section of A) in group I, B) group II, C) group III, D) group IV

CONCLUSIONS:

Results support that the efficacy of BMP-7 on allograft integration can be improved through the addition of responsive cells.

REFERENCES: ¹ Lietman SA., et al. *J Bone Joint Surg Br*, 2005, 87(9):1292–7. ² Mankin HJ., et al. *Clin Orthop Relat Res*. 1996; 324:86–97. ³ Lucarelli E., et al. *Clin Orthop Relat Res*. 2005; 435:62–8.

ACKNOWLEDGEMENTS: This work was supported in part by a grant by Stryker Biotech Inc.