

ECTOPIC BONE FORMATION IN BONE MARROW STEM CELL SEEDED CALCIUM PHOSPHATE SCAFFOLDS AS COMPARED TO AUTOGRAFT AND (CELL SEEDED) ALLOGRAFT

J.O. Eniwumide¹, H. Yuan^{2,3}, S.H. Cartmell⁴, G.J. Meijer⁵ and J.D. de Bruijn^{1,2*}

¹Department of Materials, Queen Mary University of London, London, E1 4NS, U.K.

²Progentix BV, Prof Bronkhorstlaan 10-D, 3723 MB Bilthoven, The Netherlands

³Tissue Regeneration Department, BMTI, University of Twente, 7500 AE Enschede, The Netherlands

⁴Institute of Science & Technology in Medicine, Keele University, Stoke-on-Trent, ST4 7QB, U.K.

⁵Department of Oral Maxillofacial Surgery, University Medical Centre Utrecht, Heidelberglaan 100, 3584 CX, Utrecht, The Netherlands

Abstract

Improvements to current therapeutic strategies are needed for the treatment of skeletal defects. Bone tissue engineering offers potential advantages to these strategies. In this study, ectopic bone formation in a range of scaffolds was assessed. Vital autograft and devitalised allograft served as controls and the experimental groups comprised autologous bone marrow derived stem cell seeded allograft, biphasic calcium phosphate (BCP) and tricalcium phosphate (TCP), respectively. All implants were implanted in the back muscle of adult Dutch milk goats for 12 weeks. Micro-computed tomography (μ CT) analysis and histomorphometry was performed to evaluate and quantify ectopic bone formation. In good agreement, both μ CT and histomorphometric analysis demonstrated a significant increase in bone formation by cell-seeded calcium phosphate scaffolds as compared to the autograft, allograft and cell-seeded allograft implants. An extensive resorption of the autograft, allograft and cell-seeded allograft implants was observed by histology and confirmed by histomorphometry. Cell-seeded TCP implants also showed distinct signs of degradation with histomorphometry and μ CT, while the degradation of the cell-seeded BCP implants was negligible. These results indicate that cell-seeded calcium phosphate scaffolds are superior to autograft, allograft or cell-seeded allograft in terms of bone formation at ectopic implantation sites. In addition, the usefulness of μ CT for the efficient and non-destructive analysis of mineralised bone and calcium phosphate scaffold was demonstrated.

Key Words: bone tissue engineering, mesenchymal stem cells, *in vivo* test, calcium phosphate, histomorphometry, microcomputed tomography (μ CT).

Introduction

Natural bone grafts that are used in regenerative medicine to stimulate bone formation may either be derived from a donor (allograft) or harvested from the patient (autograft). These bone grafts provide support, fill voids and enhance biological repair of skeletal defects. Autograft is currently the gold standard due to its superior osteogenic, osteoinductive and osteoconductive properties (Parikh, 2002). Its limitations however, include an additional surgical procedure for harvesting, which may lead to donor site morbidity. The risk of this increases with the amount of bone harvested, so that limited quantities are available. Moreover, bleeding, haematoma, infection, and chronic pain are common complications of bone graft harvest (Banwart *et al.*, 1995). Allograft has other limitations such as the possibility of disease transmission from donor to recipient and immunogenic reactions (Friedlaender, 1983). Tissue engineering provides a promising alternative to autograft and allograft by combining bone marrow stem cells with a suitable biomaterial scaffold, thus creating a bone graft equivalent to autograft. Several authors have evaluated and confirmed the feasibility of this approach in ectopic (Anselme *et al.*, 1999; Kruyt *et al.*, 2003) and orthotopic (Bruder *et al.*, 1998; Petite *et al.*, 2000) implantation sites in a range of animal models. Different calcium phosphate materials, including biphasic calcium phosphate (BCP) and tricalcium phosphate (TCP) have been evaluated in ectopic sites (Yuan *et al.*, 1998). These studies indicated that a specific group of calcium phosphates which have bone inducing capacities in goats and dogs (Yuan *et al.*, 2001; 2002), could be good bone tissue engineering scaffolds.

Currently, *in vivo* bone formation is commonly analysed using histomorphometric techniques on multiple histological sections (Martin *et al.*, 2002; Kruyt *et al.*, 2004a&b; Vogelin *et al.*, 2005). The data collected is extrapolated to obtain a value for bone content in the 3D structure. However, this does not provide a reliable measurement of bone volume. Moreover, histomorphometry is both destructive and labour intensive, making it impractical for online monitoring of bone repair *in vivo*. Micro-computed tomography (μ CT) may be a suitable alternative for non-destructive quantification of bone formation (Hildebrand *et al.*, 1999; Cartmell *et al.*, 2004; Hedberg *et al.*, 2005). The technique involves

*Address for correspondence:

J.D. de Bruijn

Department of Materials

Queen Mary University of London

Mile End Road, London, E1 4NS, U.K.

Telephone Number: +44-20-8981-6310

E-mail: j.d.debruijn@qmul.ac.uk

focussing an x-ray to irradiate a specimen on a rotating stage. Data collected by detectors is used to generate cross-sectional images. Differences in x-ray attenuation are used to differentiate bone from its surroundings. The potential of both histomorphometry and μ CT have been compared in numerous studies (Schmidt *et al.*, 2003). For example, measuring bone mineral density in bone biopsies (Won *et al.*, 2003); the effects of mechanical loading applied on rabbit's cancellous bone on the formation and realignment of trabecular bone (Van der Meulen *et al.*, 2006); bone formation in response to calciotropic hormone administration (Muller *et al.*, 1998; 1996; Schneider *et al.*, 2003); and studying the microstructure of calcium phosphate granules used for tissue engineering (Le Nihouannen *et al.*, 2006).

In the current study, we compared the bone forming potential of stem cell-seeded calcium phosphate scaffolds with the gold standard autograft, allograft or stem cell-seeded allograft in ectopic implantation sites of adult Dutch milk goats. In addition, the usefulness of μ CT for efficient and non-destructive analysis of mineralised bone and calcium phosphate scaffold was evaluated and compared to conventional histomorphometry.

Materials and Methods

Scaffolds

Macroporous biphasic calcium phosphate (BCP) and tricalcium phosphate (TCP) scaffolds were prepared as previously described (Yuan *et al.*, 2001) and made into 1-3mm diameter particles. The two ceramics had similar porosities ($70\pm 5\%$ in volume) and the pore size ranged between $1\mu\text{m}$ and $1000\mu\text{m}$. BCP contained $80\pm 5\text{wt}\%$ hydroxyapatite and $20\pm 5\text{wt}\%$ β -tricalcium phosphate, while TCP was mainly comprised of β -tricalcium phosphate and a trace of hydroxyapatite. Autograft was obtained from the iliac wing of Dutch milk goats, and minced to 1-3mm chips during surgery. Allograft chips were prepared from the femoral cortex of goats sacrificed in other studies as follows: After aseptic removal of all soft tissues (including periosteum and cartilage), the bone marrow contents were flushed out. The samples were then either stored at -80°C in a sterile bag for later processing or used immediately to prepare bone chips. The femoral cortex was cut into small pieces followed by a grinding step to produce 1-3mm chips. These chips were frozen twice in liquid nitrogen for 5 minutes, defatted and cleaned for 20 minutes in an equal volume of chloroform/methanol mixture, and vacuum-dried over a 48-hour period. Finally, the allograft chips were sterilised using a low dosage Gamma irradiation ($10\text{-}15\text{kGy}$).

Bone Marrow Harvest and Culture

Ten female Dutch milk goats were anaesthetised using Domosedan ($1\text{ml}/20\text{kg}$), Nesdonal ($400\text{ mg}/70\text{kg}$). One or both of their iliac wings were shaved and disinfected with iodine. A small skin incision was made perpendicular to the longitudinal axis of the Iliac Crest and $20\pm 5\text{ ml}$ bone marrow was aspirated, collected in a heparinised tube and

transported to the tissue culture facility at room temperature. The nucleated cells were counted and the cells were plated at a concentration of 5×10^5 cells/ cm^2 in T75 tissue culture flasks. The cells were grown in α -MEM supplemented with 15% FBS, 0.1mM L-ascorbic acid 2-phosphate, $1\text{ng}/\text{mL}$ b-Fibroblast Growth Factor (bFGF), 2 mM L-Glutamine and antibiotics (penicillin/streptomycin). Medium was refreshed twice a week. After 8-10 days P0 cells were harvested with 0.25% trypsin in EDTA and re-plated at a cell density of $2,500$ cells/ cm^2 . At near confluence, P1 cells were cryopreserved at 10 million cells per vial.

Per-operative Cell Seeding of Scaffolds

Cryopreserved (P1) cells were re-plated at a cell density of $2,500$ cells/ cm^2 in alpha MEM as described above, with the addition of 10 nM dexamethasone to stimulate osteogenic differentiation. At near confluency, P2 cells were harvested with 0.25% trypsin in EDTA and re-suspended at a density of 20×10^6 cells/ ml alpha-MEM plus 1% Penicillin/Streptomycin and transported to the animal facility. Autologous plasma was prepared by centrifuging peripheral blood at $3,000\text{g}$ for 4 minutes at 4°C . To prepare the tissue engineered implants, 1ml of each material (allograft, BCP and TCP) was firstly mixed with 0.5ml autologous stem cell suspension and then 0.5 ml plasma. This resulted in the formation of a clot comprising the scaffolds and the expanded autologous stem cells.

Implantation and Explantation

A total of 10 goats were used and in each goat, autograft, allograft, allograft with cells, BCP with cells (TE-BCP) and TCP with cells (TE-TCP) were implanted. The back skin of each goat was shaved, disinfected with 1% iodine (in 70% ethanol) and a longitudinal incision was made. After the muscles were exposed, a muscle pouch was prepared for each implant by blunt separation and the implants inserted. The defects were closed with vicryl sutures. The goats were sacrificed after 12 weeks by an intravenous administration of Euthesaat and the implants were harvested with the surrounding tissues, fixed in 4% paraformaldehyde and 5% glutaraldehyde at 4°C for a week.

Histomorphometry

The fixed explants were rinsed for 24 hours in PBS, dehydrated and embedded in Methyl Methacrylate (MMA). Approximately $10\mu\text{m}$ thick sections were made using a Leica (Leica Microsystems, Wetzlar, Germany) saw and stained with methylene blue and basic fuchsin. Histomorphometric analysis of the sections was performed as previously described (Kruyt *et al.*, 2004a&b). Briefly, high-resolution, low-magnification (X4) micrographs were made from the histology sections (Figure 1a). On each histological section, a region of interest was determined outlining the scaffold and bone area, using Photoshop Elements 2.0 (Figure 1b). Image analysis was performed by pseudo-colouring the bone and scaffold in the micrographs red and green, respectively. For each implanted material i.e., autograft, allograft, cell seeded

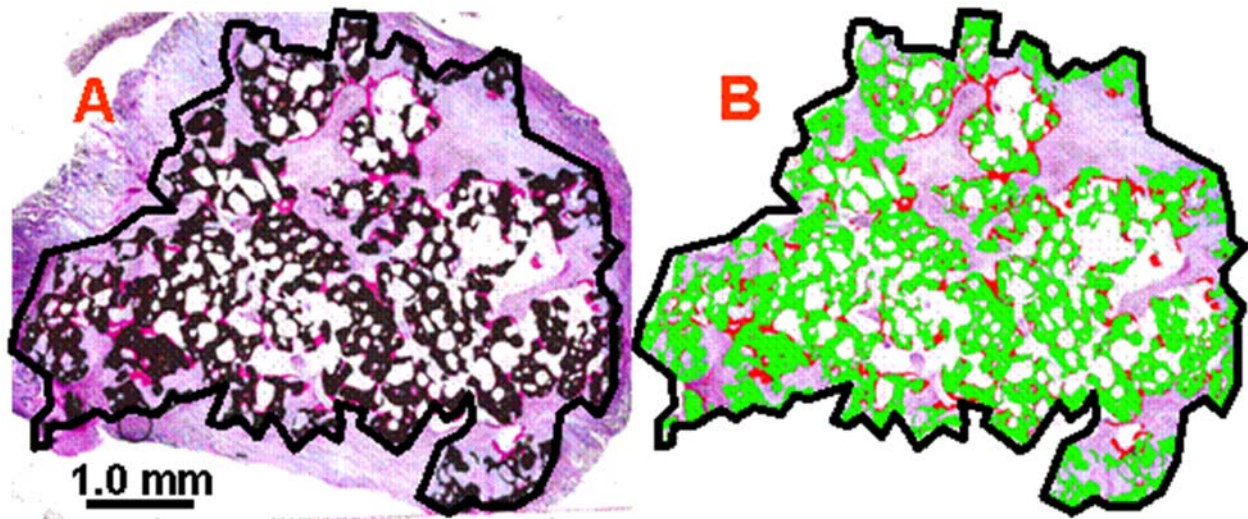


Figure 1: Histomorphometry of explants retrieved after 12 weeks. (a) Micrograph made from the 10µm-thick histological sections (b) Pseudo-coloured image, depicting bone and scaffold (red and green, respectively) within the region of interest, defined by the thick black line around the sections

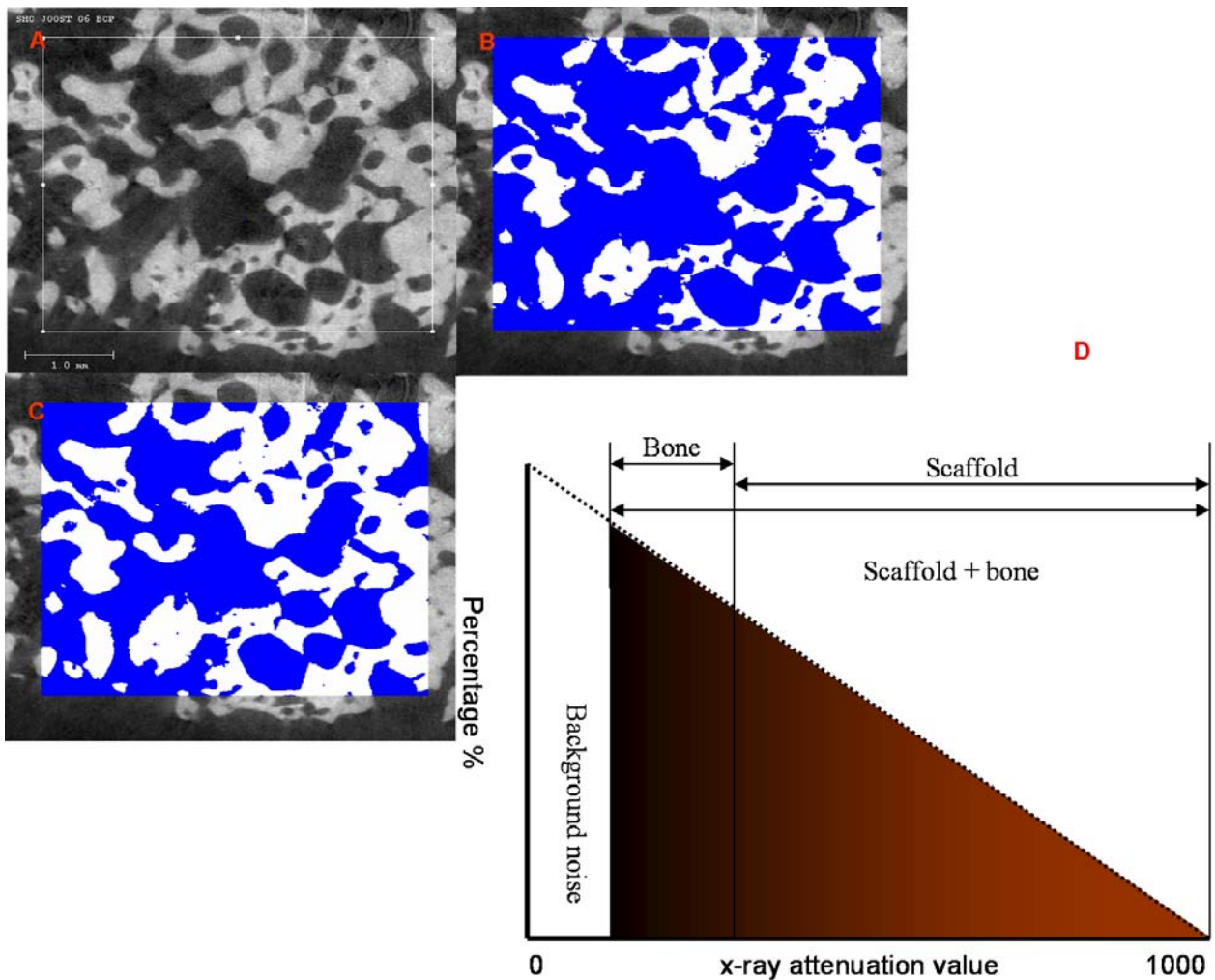


Figure 2: a) 2D micrograph of an explant scanned using μ CT (b) thresholded for scaffold and bone (c) and scaffold only. The difference between B and C is deduced to be bone. d) Schematic representation of the determination of the x-ray attenuation coefficient (Lin. Att.) and its corresponding grey pixel values for bone and scaffold. Subsequent values lower than that of bone is considered background noise and those above the bone boundary are calculated as calcium phosphate scaffold

allograft, cell seeded BCP (TE-BCP), and cell seeded TCP (TE-TCP), the bone and scaffold content was calculated as a percentage of the region of interest. A separate group of BCP and TCP granules were embedded in MMA. The density of these granules was compared with that of the implanted specimens in order to assess the resorption of the implanted BCP and TCP.

Micro Computed Tomography (μ CT)

A μ CT system (μ CT 40, Scanco Medical, Bassersdorf, Switzerland) was used as an alternative to histomorphometry, to image and quantify the amount and distribution of bone and scaffold in the explants. The imaging and measurements were conducted as previously described by Lin *et al.* (2003). The optimized settings of 15 μ m voxel resolution and 120ms integration time were used to scan the MMA-embedded explants. These samples were constructed into isotropic 2D sections (Figure 2a). The respective linear attenuation coefficients were determined and used to distinguish bone, scaffold and background noise. The threshold values were used to estimate the proportion of grey pixels within the regions of interest corresponding to bone + scaffold (Figure 2b), and to scaffold alone (Figure 2c) in representative 2D slices. The difference between the two values was deduced to be bone. Furthermore, grey pixels lower than the lower threshold limit of bone and scaffold were associated with background noise. The 2D slices were compiled and rendered into 3D images using the threshold values deduced for the bone and scaffold.

Results

Histology and Histomorphometry

Histological observation of the autograft (Figure 3a, b), allograft, cell seeded allograft (TE-Allograft) (Figure 3c, d) explants revealed considerable amounts of implant resorption. Due to the severity of their resorption, allograft, TE-allograft and autograft samples could only be retrieved from 5 of the 10 goats used. In most histological sections, allografts and TE-allografts (Figure 3c-d) were not readily detectable. Seemingly, the rate of implant resorption was higher than neo-bone formation. In contrast, the TE-BCP and TE-TCP samples showed abundant signs of bone formation, with layers of secretory osteoblasts, osteoid and mineralised bone matrix with embedded osteocytes (Figure 3e-h) TCP showed distinct signs of degradation by the presence of small fragments. No obvious signs of degradation were seen of the BCP implants.

The results of histomorphometric analysis are illustrated in Figures 4 and 5. After the 12-week implantation period, similar amounts of bone formation were observed for allograft ($0.8 \pm 0.9\%$), TE-allograft ($1.6 \pm 1.4\%$), and autograft ($1.7 \pm 1.7\%$) explants (Figure 4). Histomorphometry showed that considerably more bone was formed in the TE-BCP ($4.4 \pm 1.3\%$) and TE-TCP ($7.2 \pm 1.9\%$, Figure 5) implants as compared to the natural bone grafts (autograft and allograft: 1.7% and 0.8%, respectively). Figure 5 demonstrates that the resorption of

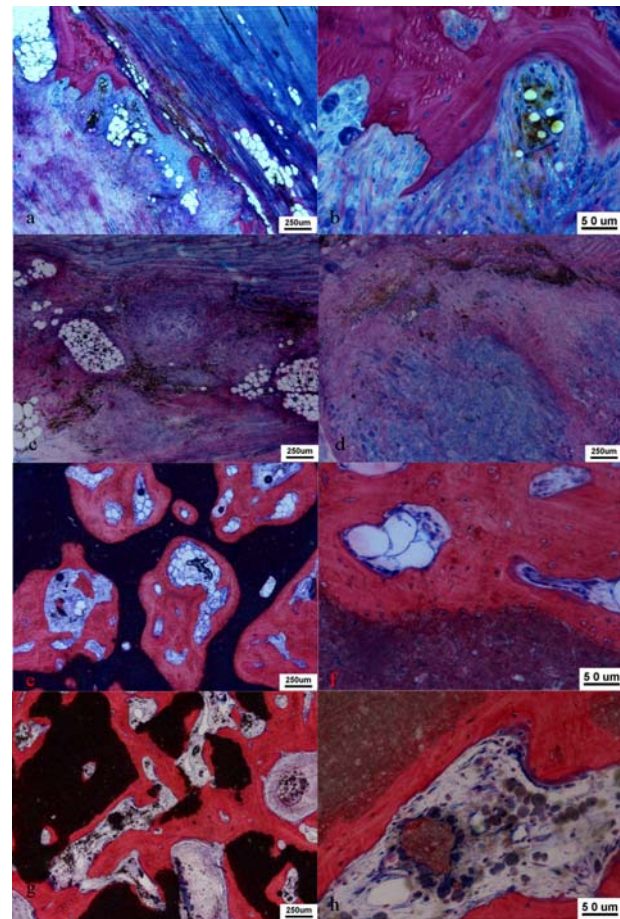


Figure 3: Representative micrographs of: a), autologous implant, showing some bone and intermittent residues of the resorbed implant and (b) bone forming cells. Images c and d, which demonstrate absolute resorption of original implants, with little bone formation, were obtained from allografts and TE-allografts, respectively. Micrographs e and f were typical of the TE-BCP implants. The extent of bone formation is made clear in image e, while the presence of bone forming cells may be observed in f. Similarly, micrographs g and h, obtained from the TE-TCP explants illustrate bone formation and scaffold degradation (g). In fact, resorption residues of TCP are observable in h. Additionally, bone forming cells may be seen on the surfaces of the neo-bone tissues.

TCP implants over the 12 weeks averaged 38.9%, whereas little degradation of BCP implants was observed (5.1%).

Micro Computed Tomography (μ CT) Analyses

Both the scaffold and the bone contents of the samples were readily imaged using μ CT. For both the TE-BCP and TE-TCP, typical 3D images of bone and scaffold resulting from the selected threshold values are shown in Figure 6. It was observed that both scaffold and bone were ubiquitous throughout the explants. However, the scaffolds appear denser than bone, in both explants. The difference in their appearances is due to the higher x-ray attenuation properties of the calcium phosphate scaffolds. Although a clear difference was observable between the scaffolds and

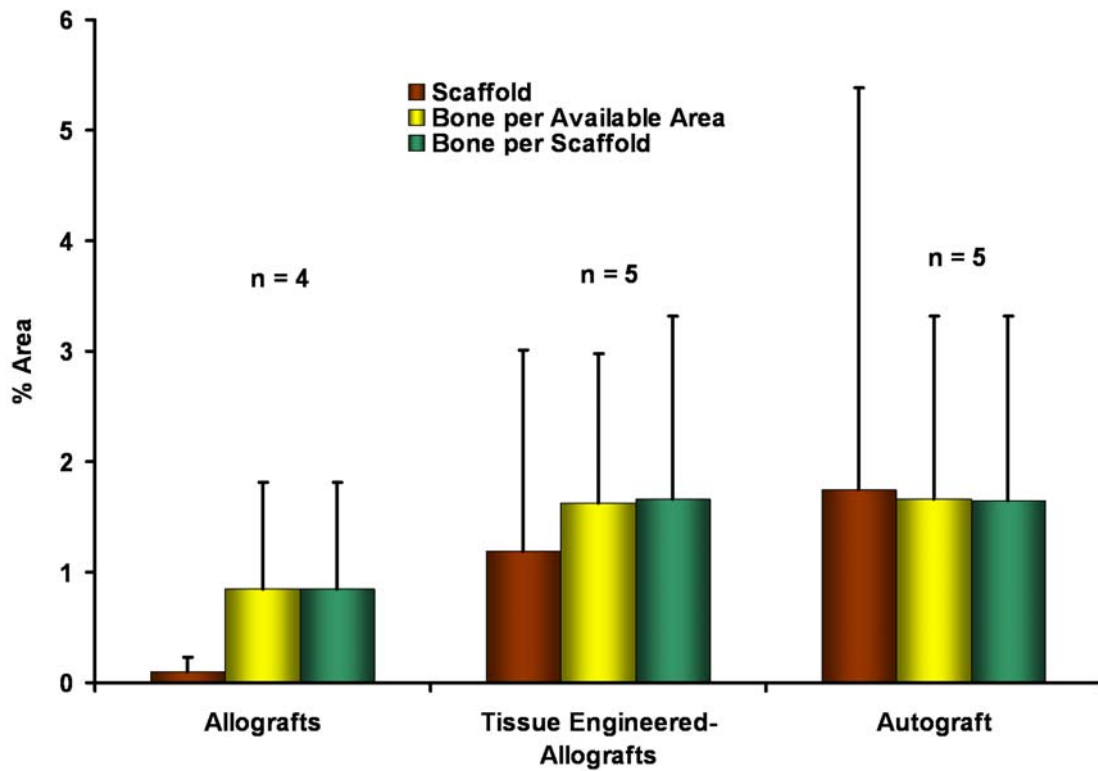


Figure 4: Histomorphometric analyses of scaffold and bone contents within allograft, TE-allograft and autograft explants that were retrieved following implantation. The error bars represent standard deviation of a sample size, n of 4 to 5.

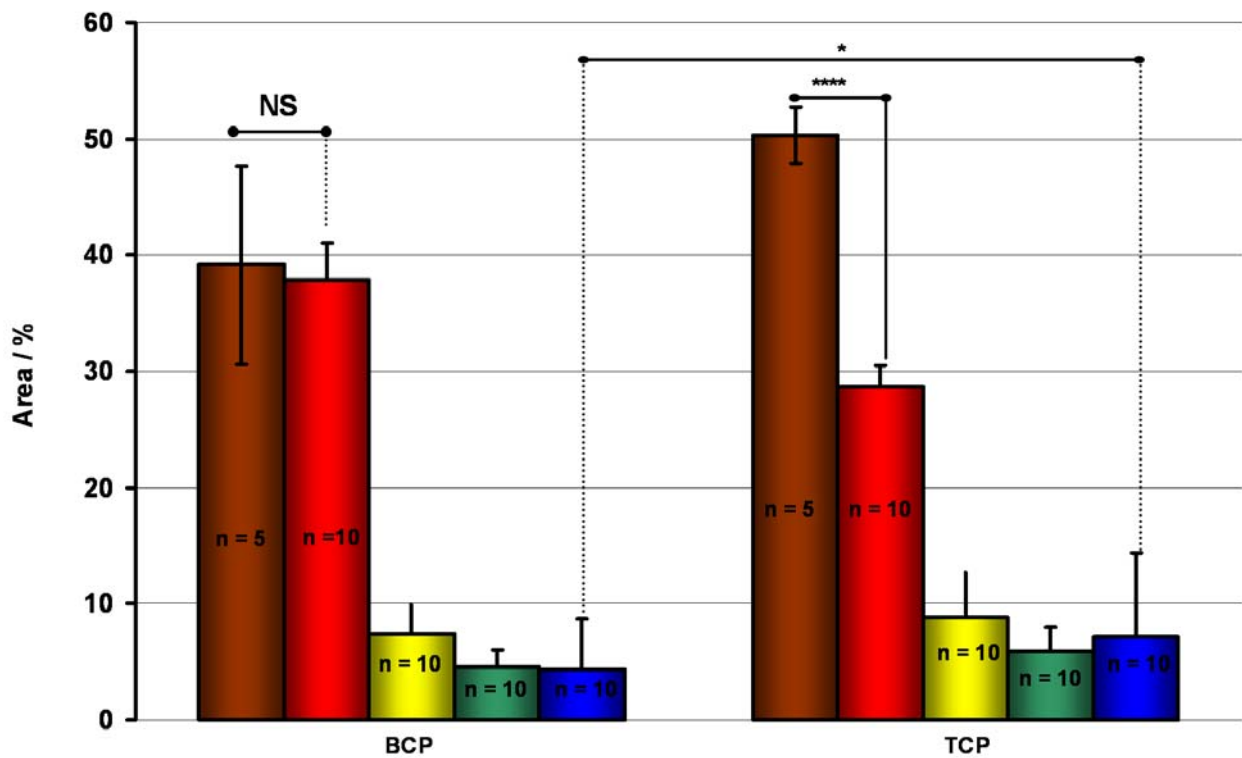


Figure 5: Histomorphometric analyses of the TE-BCP and TE-TCP explants. These show; the average scaffold content of the retrieved explants (red), pre-implantation values (brown), bone formation is per the available area, bone formation per the total explant and as a function of the degrading scaffold (yellow, green and blue, respectively). The error bars represent the standard deviation of sample sizes n, indicated on the bars. * $p < 0.05$ **** $p < 0.001$ and NS = not significant




Figure 6: 3D μ CT images of the tissue engineered BCP a) and b) TCP explants. The images have been sectioned to help illustrate the distribution of the neo-bone (red) within the scaffold (grey).

bone, such difference was not observable between BCP and TCP from μ CT images.

Micro-CT analyses conducted for the tissue engineered BCP and BCP samples were compared with histomorphometric analyses of the same samples. Both the scaffold and bone contents were measured in proportion to the volume of the explants and to representative slices of the scanned sample. The latter provided 2D analyses that can be directly compared with the calculations made using histomorphometry. The results were pooled and presented for TE-BCP and TE-TCP (Figure 7a and b, correspondingly). It may be observed that both the histomorphometric and μ CT analyses indicate the relatively high scaffold contents compared to bone. Figure 7, which compares the two methods of measurement, clearly shows the differences between the histomorphometry and the 2D μ CT analyses of representative surfaces, particularly in measuring bone contents. For either the TE-BCP or TE-TCP, there were as much as 100% differences of the bone volume, measured using the μ CT instrument measurements in comparison to the histology image analysis. Interestingly, with the exception of the original scaffolds, which had not been implanted, scaffold volume was also significantly higher by the μ CT, though to a lesser extent. These inconsistencies are notable in both, 2D measurements (of representative surfaces) and the 3D measurements of the entire explants. Typically, there were good agreements between the μ CT analyses made from chosen representative surfaces and

the volumetric (3D) analyses. The only disagreement between the two methods occurred in the calculation of bone, when the extent of scaffold resorption is taken into account. Indeed this disagreement occurred with both the tissue engineered BCP and TCP explants.

Discussion

The current study aimed to compare bone formation in cell-seeded calcium phosphate scaffolds, the gold standard autograft, allograft or cell-seeded allograft in ectopic implantation sites in the goat. In addition, the potential of μ CT, which offers an efficient and non-destructive analysis of mineralised bone and calcium phosphate scaffold was evaluated and compared to conventional histomorphometry. Dutch milk goats were chosen as previous studies have demonstrated their suitability to assess tissue engineered constructs in an ectopic environment (Yuan *et al.*, 2001; 2002; Kruyt *et al.*, 2004a&b). The significance of cells for bone formation in calcium phosphate implants has been demonstrated previously (Kruiy *et al.*, 2003; Van Gaalen *et al.*, 2004), whereby significant differences in the bone forming capacities of ectopically implanted porous hydroxyapatite granules with and without osteoprogenitor cells indicated the crucial role of the cells in bone formation. However, in the present study, the difference in bone formation associated with allograft chips with and without the cells

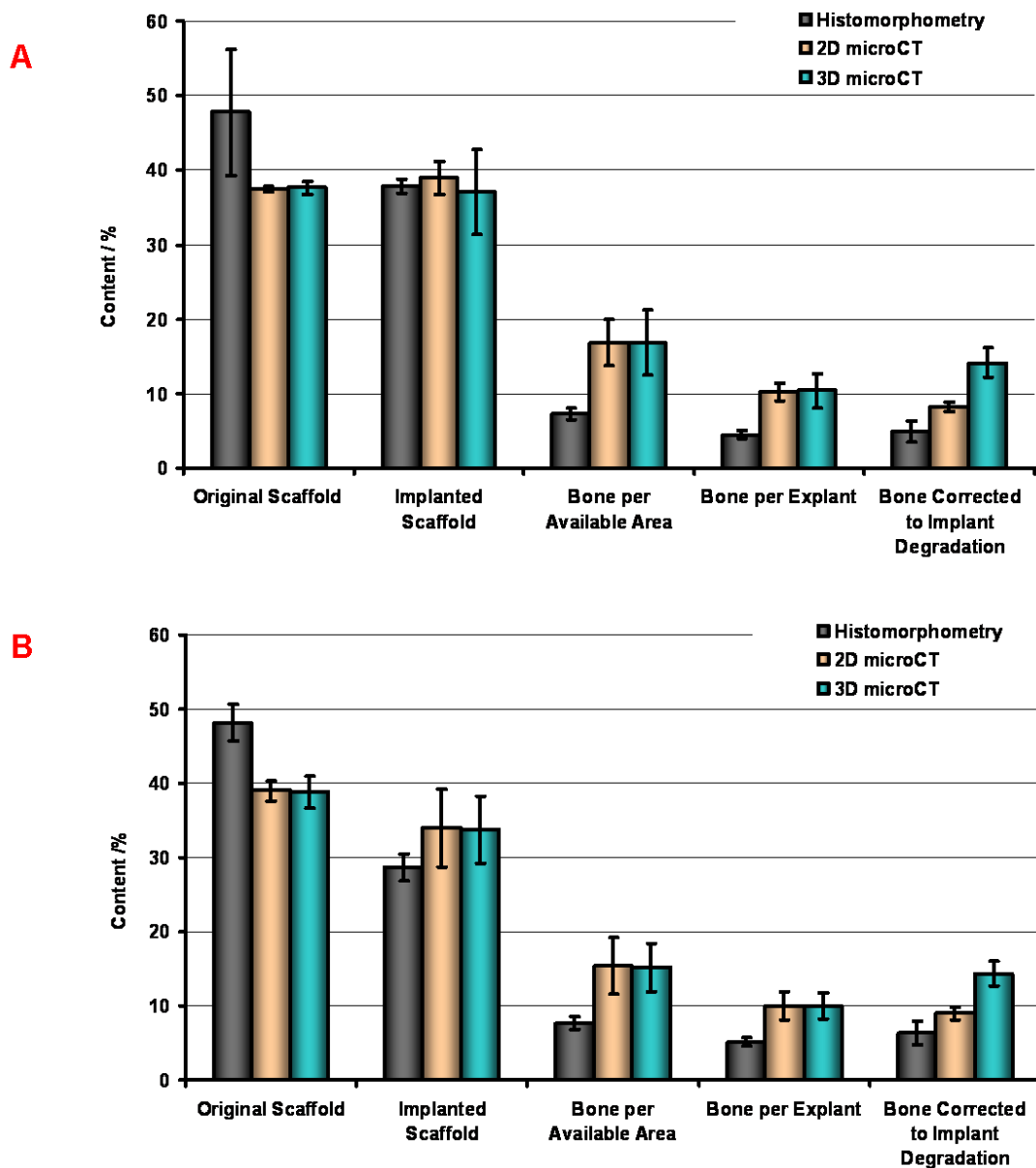


Figure 7: Direct comparisons of the two parameters (bone and scaffold content) as measured using histomorphometry and μ CT for a) TE-BCP and b) TE-TCP

was not clearly demonstrated, perhaps due to the high resorption rate of the implants. For this reason also, bone formation recorded for allograft and autograft explants were not significant. Indeed, literatures exist which suggest little difference between allografts and autografts implants (Buttermann *et al.*, 1997), although the general consensus is that autografts have superior bone forming capacity (An *et al.*, 1995).

The potential of BCP and TCP scaffolds to induce bone formation in ectopic sites has been previously demonstrated by Yuan and co-workers (Yuan *et al.*, 2001, 2002). They showed that BCP or TCP induced bone formation (osteinduction) in ectopic sites varied with animal species (Yuan *et al.*, 2006). Furthermore, they observed an average of 30% bone formation in BCP in dogs after 12 weeks ((Yuan *et al.*, 2006), while less than 1% bone in goats (Yuan *et al.*, 2002)). The rate of bone

synthesis over the implantation period observed by Yuan in BCP alone in goats averaged at 0.08% per week, whereas, the rate observed in the present study was 0.67% per week. This indicates the relevance of cells for bone formation in ectopic sites.

The extent of resorption that had occurred with the autograft and allograft implants over the 12 week implantation period was significant. Only half of the implants could be retrieved while histological signs of bone formation were only observed for some of the autograft implants. This high resorption rate may explain the low levels of bone formation observed in autograft and allograft explants. Conceivably, the implants may have degraded faster than the rate of bone formation, reducing the available scaffold surface on which bone may form. Clinically, these are important findings as they indicate that natural bone grafts may not always be the material of

choice in ectopic implantation sites such as postero-lateral spine fusion. The observed high resorption rate of autograft and allograft may explain the large failure rate for bony fusion at this implantation site (Boden, 1998; Vccaro *et al.*, 2002). The observed bone formation with the tissue engineered-TCP and BCP scaffolds and their respective slight and negligible degradation profiles make these materials promising alternatives for the natural bone grafts. The mild dissolution of TE-TCP may be coupled with its superior bone formation, as observed in the present study compared to TE-BCP. Based on similar findings, it has been suggested that resorption of calcium phosphates provide a calcium/phosphate environment conducive for bone formation (Yuan *et al.*, 1998).

For both TE-BCP and TE-TCP, scaffold resorption was evaluated by comparing the scaffold content (as a percentage of the total volume of the retrieved implants), with that of non-implanted BCP and TCP scaffolds, fixed in MMA and sectioned similarly to the explants. This approach is limiting, due to the fact that the method of intra-muscular implantation is such that the granules are forced into the implantation site, and the volumes of space taken up by the implants are unknown. Therefore, the volume of the retrieved explants, as a percentage of the original implant volume cannot be determined. It is conceivable that the explants may have a different pore geometry post implantation, due to the development of connective tissues over the 12 weeks, and consequently, the scaffold and bone contents as a percentage of the explant volume may not equate to that of the original implant.

The relative proportions of calcium phosphate scaffold and bone present in the explants, as measured using both histomorphometry and μ CT correlated significantly. The general agreement between the 2D and 3D μ CT analyses suggests that the slices used in the 2D calculations were fair representations of the entire explants. However, such conclusions could not be drawn for the histomorphometry analyses, as only one surface was analysed per explant. The destructive nature of histomorphometry made examination of multiple sections of the same explants unfeasible. It is noteworthy, that good agreements were obtained using histomorphometry between samples implanted in the 10 different goats. Therefore, though intra-explant agreement could not be ascertained, i.e., it is not possible to assess whether the histology slides made from a plane representative of the entire explants, good inter-explants agreement, i.e. between different goats may be assumed.

Both the 2D and 3D measurements, made using μ CT showed an overestimation of both the bone and scaffold contents. This overestimation may have originated from the process of obtaining threshold values during their calculation. The pore/bone/scaffold interphase, as imaged by the μ CT apparatus is less well defined than the histological sections. The overestimation occurring at both the 2D and 3D measurements support the theory of its origin being at the thresholding phase of the data analysis (Figure 2).

The x-ray attenuation of the micropores were indistinguishable from that of the background noise, and

thus, all values lower than the lower boundary of bone were treated as background noise and were therefore neglected. In contrast, bone and scaffold materials were readily identified using histological stains (Figure 3), as both were represented by distinct colours and their boundaries were better defined than the grey pixels obtained using the μ CT apparatus (Figure 2). Moreover, histomorphometry was useful for visualising substances such as fat globules, cells and pores (not included in figures), which are otherwise transparent to x-ray. For this reason, it may be expected that the proportion of grey pixels associated with background noise in the μ CT may not be a true representation of the actual pore volume. However, the relatively high bone and scaffold content calculated by μ CT is likely to result from an underestimation of the background grey pixels of the x-ray-transparent materials. Indeed, histomorphometric analyses showed that pore volume, post implantation for TE-BCP and TE-TCP were approximately 58% and 63%, respectively. However, similar calculation, using μ CT were 52% and 56%, respectively (data not shown). It is noteworthy that though histological method is more commonly used in these studies, the quality of the staining may vary with human error, which in turn may influence the pseudo-colouring of the scanned image and ultimately, the calculated values. Such errors may be minimised when using μ CT during optimisation, and thus the true value of bone and scaffold contents in the current study may be in between the two analysis techniques. Additionally, the destructive nature of the histological procedure makes it very difficult to measure the true bone and scaffold content of the retrieved explant. Though not exploited in the current study, the use of μ CT makes this analysis possible, which is crucial in measuring the true resorption of the implant. Furthermore, the adaptation and optimisation of such technique for *in vivo* analyses may enable bone formation and resorption rate of implants to be monitored.

Conclusions

From this study, it can be concluded that ectopic bone formation by autologous, bone marrow derived stem cell-seeded calcium phosphate scaffolds is superior to that of autograft or (cell seeded) allograft. Moreover, the mild resorption of TCP *in vivo* provides an environment that is conducive to bone formation and results in significantly ($p < 0.001$) more bone formation as compared to autograft, (cell seeded) allograft and cell seeded BCP. Finally, we confirm that micro computed tomography enables an efficient, non-destructive, 3D evaluation of bone and calcium phosphate scaffolds.

References

An HS, Lynch K, Toth J (1995) Prospective comparison of autograft vs. allograft for adult posterolateral lumbar spine fusion: differences among freeze-dried, frozen, and mixed grafts. *J Spinal Disord* **8**: 131-135.

- Anselme K, Noel B, Flautre B, Blary MC, Delecourt C, Descamps M, Hardouin P (1999) Association of porous hydroxyapatite and bone marrow cells for bone regeneration. *Bone* **25**: 51S-54S.
- Banwart JC, Asher MA, Hassanein RS (1995) Iliac crest bone graft harvest donor site morbidity: A statistical evaluation. *Spine* **20**: 1055-1060.
- Boden SD (1998) The biology of posterolateral lumbar spinal fusion. *Orthop Clin North Am* **29**: 603-619.
- Bruder SP, Kraus KH, Goldberg VM, Kadiyala S (1998) The effect of implants loaded with autologous mesenchymal stem cells on the healing of canine segmental bone defects. *J Bone Joint Surg Am* **80**: 985-996.
- Buttermann GR, Glazer PA, Hu SS, Bradford DS (1997) Revision of failed lumbar fusions. A comparison of anterior autograft and allograft. *Spine* **22**: 2748-2755.
- Cartmell S, Huynh K, Lin A, Nagaraja S, Guldberg R (2004) Quantitative Microcomputed Tomography Analysis of Mineralization within Three-Dimensional Scaffolds *in vitro*. *J Biomed Mater Res A* **69**: 97-104.
- Friedlaender GE (1983) Immune responses to osteochondral allografts. Current knowledge and future directions. *Clin Orthop Relat Res* **174**: 58-68.
- Hedberg EL, Kroese-Deutman HC, Shih CK, Lemoine JJ, Liebschner MA, Miller MJ, Yasko AW, Crowther RS, Carney DH, Mikos AG, Jansen JA (2005) Methods: a comparative analysis of radiography, microcomputed tomography, and histology for bone tissue engineering. *Tissue Eng* **11**: 1356-1367.
- Hildebrand T, Laib A, Muller R, Dequeker J, Ruegsegger P (1999) Direct three-dimensional morphometric analysis of human cancellous bone: microstructural data from spine, femur, iliac crest, and calcaneus. *J Bone Miner Res* **14**: 1167-1174.
- Kruyt MC, de Bruijn JD, Wilson CE, Oner FC, van Blitterswijk CA, Verbout AJ, Dhert WJ (2003) Viable osteogenic cells are obligatory for tissue-engineered ectopic bone formation in goats. *Tissue Eng* **9**: 327-336.
- Kruyt MC, Dhert WJ, Yuan H, Wilson CE, van Blitterswijk CA, Verbout AJ, de Bruijn JD (2004a) Bone tissue engineering in a critical size defect compared to ectopic implantations in the goat. *J Orthop Res* **22**: 544-551.
- Kruyt MC, Dhert WJ, Oner C, van Blitterswijk CA, Verbout AJ, de Bruijn JD (2004b) Optimization of bone tissue engineering in goats. *J Biomed Mater Res: B Appl Biomaterials* **69**: 113-120.
- Le Nihouannen D, Guehennec LL, Rouillon T, Pilet P, Bilban M, Layrolle P, Daculsi G (2006) Micro-architecture of calcium phosphate granules and fibrin glue composites for bone tissue engineering. *Biomaterials* **27**: 2716-2722.
- Lin AS, Barrows TH, Cartmell SH, Guldberg RE (2003) Microarchitectural and mechanical characterization of oriented porous polymer scaffolds. *Biomaterials* **24**: 481-489.
- Martin I, Mastrogiacomo M, De Leo G, Muraglia A, Beltrame F, Cancedda R, Quarto R (2002) Fluorescence microscopy imaging of bone for automated histomorphometry. *Tissue Eng* **8**: 847-852.
- Muller R, Van Campenhout H, Van Damme B, Van Der Perre G, Dequeker J, Hildebrand T, Ruegsegger P (1998) Morphometric analysis of human bone biopsies: a quantitative structural comparison of histological sections and micro-computed tomography. *Bone* **23**: 59-66.
- Muller R, Hahn M, Vogel M, Delling G, Ruegsegger P (1996) Morphometric Analysis of noninvasively assessed bone biopsies: comparison of high-resolution computed tomography and histologic sections. *Bone* **18**: 215-220.
- Parikh SN (2002) Bone graft substitutes: Past, present, future. *J Postgrad Med* **48**: 142-148.
- Petite H, Viateau V, Bensaid W, Meunier A, de Pollak C, Bourguignon M, Oudina K, Sedel L, Guillemin G (2000) Tissue-engineered bone regeneration. *Nat Biotechnol* **18**: 929-930.
- Schmidt C, Priemel M, Kohler T, Weusten A, Muller R, Amling M, Eckstein F (2003) Precision and accuracy of peripheral quantitative computed tomography (pQCT) in the mouse skeleton compared with histology and microcomputed tomography (microCT). *J Bone Miner Res* **18**: 1486-1496.
- Schneider A, Taboas JM, McCauley LK, Krebsbach PH (2003) Skeletal homeostasis in tissue-engineered bone. *J Orthop Res* **21**: 859-864.
- Vaccaro AR, Chiba K, Heller JG, Patel TCh, Thalgott JS, Truumees E, Fischgrund JS, Craig MR, Berta SC, Wang JC (2002) Bone grafting alternatives in spinal surgery. *Spine J* **2**: 206-215.
- Van der Meulen MC, Morgan TG, Yang X, Baldini TH, Myers ER, Wright TM, Bostrom MP (2006) Cancellous bone adaptation to *in vivo* loading in a rabbit model. *Bone* **38**: 871-877.
- Van Gaalen SM, Dhert WJ, van den Muysenberg A, Oner FC, van Blitterswijk C, verbout AJ, de Bruijn JD (2004) Bone tissue engineering for spine fusion: an experimental study on ectopic and orthotopic implants in rats. *Tissue Eng* **10**: 231-239.
- Vogelin E, Jones NF, Huang JI, Brekke JH, Lieberman JR (2005) Healing of a critical-sized defect in the rat femur with use of a vascularized periosteal flap, a biodegradable matrix, and bone morphogenetic protein. *J Bone Joint Surg Am* **87**: 1323-1331.
- Won YY, Chung YS, Park YK, Yoo VY (2003) Correlations between microcomputed tomography and bone histomorphometry in Korean young females. *Yonsei Med J* **44**: 811-815.
- Yuan H, Yang Z, Li Y, Zhang X, De Bruijn JD, De Groot K (1998) Osteoinduction by calcium phosphate biomaterials. *J Mater Sci: Mater Med* **9**: 723-726.
- Yuan H, Yang Z, de Bruijn JD, Groot K., Zhang X (2001) Material-dependent bone induction by calcium phosphate ceramics: a 2.5-year study in dog. *Biomaterials* **22**: 2617-2623.
- Yuan H, Van Den Doel M, Li S, Van Blitterswijk CA, De Groot K, De Bruijn JD (2002) A comparison of the osteoinductive potential of two calcium phosphate ceramics implanted intramuscularly in goats. *J Mater Sci: Mater Med* **13**: 1271-1275.
- Yuan H, van Blitterswijk CA, de Groot K, de Bruijn JD (2006) Cross-species comparison of ectopic bone formation in biphasic calcium phosphate (BCP) and hydroxyapatite (HA) scaffolds. *Tissue Eng* **12**: 1607-1615.

Discussion with Reviewers

D. Zou: The μ CT segmentation may have suffered from “skin” effect, where a layer of bone was incorrectly identified around all the surface of the granules due to the fact that the transition of greyscale from granules to background is not a perfect step function and bone has an intermediate value between granules and background. These misclassified pixels at the boundaries may account for the higher bone content in comparison to histology.

Authors: The transitions between each of the phases analysed, i.e. scaffold-bone-noise were indeed not perfect steps. In fact, each transition was characterised by a gradient of pixel intensity from one phase to the next. However, in each case, the range of pixel intensities was identified through an iterative process. Once the ranges were identified for all interphases, the median values were used for subsequent calculations. Although the issue of “skin effect” is certainly possible in these types of calculations, and if occurred, would certainly result in misclassified pixels, the use of the median values for calculations means that, statistically, over-estimation and underestimation of the bone and scaffolds are equally likely. It is worth noting that the differences between the real values and the skin-affected values may be influenced by how wide the “skin” range is. This will ultimately depend on the quality of the scans.

M. Bohner: Why would bone and allograft degrade so fast when these materials are known to degrade very slowly or not at all in orthotopic sites? The fast degradation of allograft and autograft either suggests either particle migration, a mechanical effect or an inflammatory reaction. Did you see inflammation signs?

Authors: The observed autograft and allograft resorption in ectopic sites is in agreement with a study of Kruyt *et al.* (2004c) who also showed extensive (ectopic) resorption of grafts made from corticocancellous bone. The lack of mechanical stress could have resulted in graft resorption (Wolff’s law). Also in orthotopic sites (postero-lateral spine fusion in the goat), we have observed significant resorption of corticocancellous autograft after 12 weeks of implantation. Hence, we cannot confirm that the statement that these grafts are “known to degrade very slowly or not at all in orthotopic sites” is accurate. This may, however, be the case for cortical grafts, which are sometimes used

as structural bone grafts. Evidence of a severe inflammatory reaction or of (graft) particle migration was not observed in any of the implants.

M. Bohner: The use of autograft in ectopic sites is (I believe) well documented. Did the other studies on the topic also find a large degree of resorption?

Authors: Yes, as indicated above, we have previously also observed significant autograft resorption in the same experimental model (Kruyt *et al.*, 2004c).

I. Martin: What is the relevance of ectopic models in bone formation/repair?

Authors: Ectopic models provide an implantation site that will allow the determination whether or not materials or tissue engineered constructs are osteoinductive. In cell-based tissue engineering, this model is therefore often used to determine whether the cells are osteogenic allow bone formation. There is however also a clinical relevance of an ectopic model for bone repair. In spine fusion, for example, the aim is to make a bony bridge between two vertebral bodies or spinous processes. An important area where this “fusion” has to take place is devoid of bone (i.e. surrounded by muscle), so that this can be seen as an ectopic implantation site.

I. Martin: Is the μ CT reliably allowing a clear distinction between bone tissue and scaffold material? Is that a ‘tricky’ method or would you recommend it as a general tool in the field?

Authors: Reliable determination of bone formation using μ CT depends on the type of implant used (e.g. polymer, metal or ceramic) and the “easiness” of distinguishing bone from scaffold material. Also, the quality and resolution of the scan plays an important role in determining its usefulness. It can therefore not be said whether μ CT should be used as a general tool in the field as this depends on many variables.

Additional Reference

Kruyt MC, Dhert WJ, Oner C, van Blitterswijk CA, Verbout AJ, de Bruijn JD (2004c) Osteogenicity of autologous bone transplants in the goat. *Transplantation* 77: 504-509.