

HIP RESURFACING ARTHROPLASTY: CURRENT STATUS AND FUTURE PERSPECTIVES

K. Corten^{1,3}, R. Ganz², J-P Simon³ and M. Leunig^{*,1,2}

¹Hip Service, Department of Orthopaedics, Schulthess Clinic, Zürich, Switzerland

²University of Berne, Switzerland

³Department of Orthopaedics,, Hip Unit, University Hospital Pellenberg, Belgium

Abstract

Hip resurfacing arthroplasty (HRA) is a concept of hip replacement that allows treating young active patients with a femoral bone preserving procedure. The proposed advantages of resuming an active lifestyle with increased frequency and duration of sports activities have been shown to be realistic. The 30-year cost-effectiveness in young male patients has been shown to be higher in resurfacing compared to conventional total hip replacement (THA). However, prognosticators of an inferior outcome have also been identified. The most important patient related factors are secondary osteoarthritis as the indication for surgery such as post-childhood hip disorders or AVN, female gender, smaller component sizes and older age (>65 years for males and >55 years for females). In addition, surgical technique (approach and cementing technique) and component design are also important determinant factors for the risk of failure. Moreover, concerns have surfaced with respect to high metal ion concentrations and metal ion hypersensitivities. In addition, the presumed ease of revising HRA has not reflected in improved or equal survivorship in comparison to a primary THA. This highlights the importance of identifying patient-, surgery-, and implant-related prognosticators for success or failure of HRA. Rather than vilifying the concept of hip resurfacing, detailed in depth analysis should be used to specify indications and improve implant design and surgical techniques.

Keywords: Hip resurfacing, surface replacement arthroplasty, national joint replacement registry.

Introduction

Hip resurfacing arthroplasty (HRA) is a technique of prosthetic hip replacement attempting to treat osteoarthritis (OA) of the hip with only partial resection of the femoral head (Fig. 1). The concept has been favored for young and active patients, particularly because of the femoral bone preserving nature of the procedure. Moreover, the construct is proposed to have an increased stability due to the near-anatomical diameter of the articulating surface compared with the 28- or 32-mm total hip arthroplasty (THA) components (McMinn *et al.*, 1996; Amstutz *et al.*, 1998). Therefore, HRA is presumed to more closely restore the human anatomy and physiology than conventional THA (Table 1).

However, the resurfacing concept is not new but is still surrounded with debate and controversies. The first two generations of HRA with stemless femoral components have been abandoned during the 80s due to high failure rates caused by the excessive wear of the large diameter polyethylene bearing surface (Amstutz *et al.*, 1986; Howie *et al.*, 1990; Schmalzried *et al.*, 1994). The development of metal-on-metal (MoM) bearings with improved fluid film lubrication was the most important factor in the reemergence of HRA as a concept. Metal-on-metal HRA with a cementless, porous or hydroxyapatite coated, non-modular socket in combination with a cemented, stemmed femoral component was reintroduced into clinical practice since the 90s (Schmalzried *et al.*, 1994). Wear-induced osteolysis was proposed to be eliminated by MoM bearings and several other advantages of current generation HRA were additionally mentioned by its proponents including a more precise biomechanical restoration, physiologic femoral loading and reduced stress-shielding, reduced dislocation rates, and a decreased prevalence of thrombo-embolic phenomena. The bone preserving principle at the femoral side and the presumed easier revision surgery were mentioned as the most important advantages at longer term (Table 1).

Short-term clinical follow-up reports of MoM HRA have been encouraging, (De Smet *et al.*, 2002; Amstutz *et al.*, 2004b; Daniel *et al.*, 2004; De Smet, 2005) with femoral neck fractures (Amstutz *et al.*, 2004b; Shimmin and Back, 2005; Shimmin *et al.*, 2005) and femoral loosening (Amstutz *et al.*, 2004a) being the most prevalent causes of failure, up to 5.6% and 2.3% respectively. However, these reports have been published mainly from the designer centers (Amstutz *et al.*, 2004a; Treacy *et al.*, 2005) (Table 2). The experiences of these high volume arthroplasty surgeons have led to adaptations in the techniques and, consequently, the results are still evolving (Beaulé *et al.*, 2004a; Beaulé *et al.*, 2004b; Daniel *et al.*,

*Address for correspondence:

M. Leunig

Schulthess Clinic

Lengghalde 2

CH-8008 Zürich, Switzerland

E-mail: michael.leunig@kws.ch

Table 1: Overview of the presumed advantages of HRA over THA.**Presumed advantages of HRA over THA**

Femoral bone conservation (Amstutz *et al.*, 1984; Girard *et al.*, 2006; *et al.*, 2006)

Improved function as a consequence of retention of the femoral head (Gore *et al.*, 1985)

More precise biomechanical restoration (Girard *et al.*, 2006; Gore *e.*

Decreased morbidity at the time of revision arthroplasty (Ball *et al.*,

Reduced dislocation rates (Amstutz *et al.*, 1998; McMinn *et al.*, 199

Normal femoral loading and reduced stress-shielding (Kishida *et al.*

Easier management with proximal femoral deformity (Amstutz *et al.*

Improved outcome in the event of infection (Treacy *et al.*, 2005)

Easier first time revision with less co-morbidities (Ball *et al.*, 2007;

Reduced prevalence of thromboembolic phenomena (Treacy *et al.*, 200

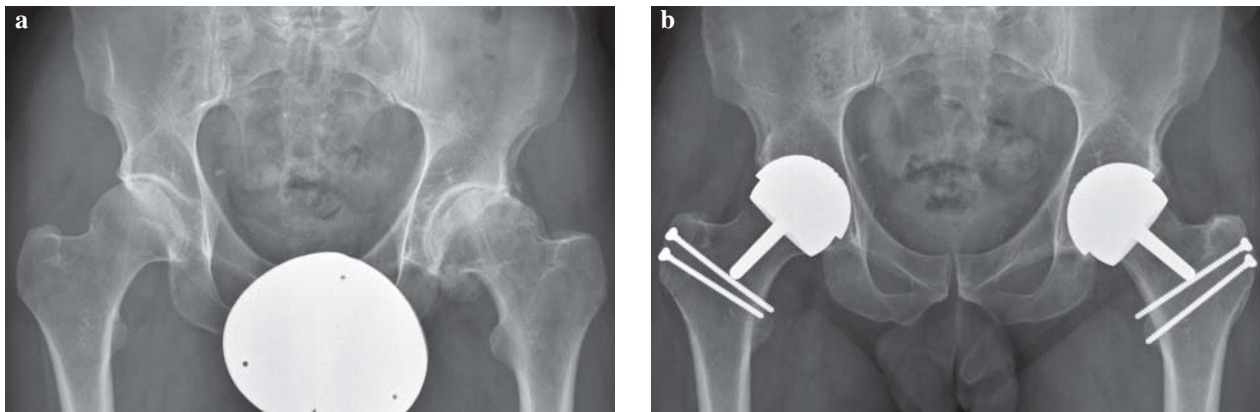


Fig. 1. (a) Radiograph of a 52-year old male patient who suffered from bilateral osteoarthritis. (b) The patient was treated by a two stage bilateral HRA using an open surgical dislocation technique with a step osteotomy of the greater trochanter.

2004; Schmalzried *et al.*, 2005). Long-term data from non-designer centers are still lacking and HRA has already a widespread use with results being published from 3 National Joint Replacement Registries (NJRR) (Corten and MacDonald, 2010; de Steiger *et al.*, 2010; Web ref. 1; Web ref. 2; Web ref. 3; Web ref. 4). Currently, concerns about HRA and specific particular HRA designs have surfaced leading to narrowing the indications and optimizing the techniques for the procedure (Corten and MacDonald, 2010; de Steiger *et al.*, 2010).

It was the aim of this report (1) to evaluate our current knowledge of the functional results, the survivorship and prognosticators for complications and failure of HRA and (2) to identify the state-of-the-art of HRA with its current weaknesses and possible improvements that could lead to more reproducible techniques and results in the future.

Materials and Methods

We searched PubMed and Medline with the terms “hip resurfacing”, “hip resurfacing arthroplasty” and “surface replacement hip”. Reports documenting on surgical technique, implant engineering and complications were

evaluated for their relevance in identifying problems and improving the procedure to the current state-of-the art of HRA. Clinical follow-up reports of HRA with the following inclusion criteria were evaluated: (1) survivorship analysis at a minimum of 5 years and (2) a combination of primary and secondary osteoarthritis as the indication for HRA. We excluded manuscripts reporting only on secondary osteoarthritis, as the results from these reports were – in general – also included by the same authors in other reports where the overall results of their HRA series were evaluated. This left twelve papers that met the inclusion criteria (Table 2). The reports were assessed for indication of surgery, follow-up, revision rates, indication of revision, reoperations other than revision and complication rate (with all reoperations included as complications). The data from the Annual Reports of the Australian (Web ref. 4), Swedish (Web ref. 2; Web ref. 3) and English (and Welsh) National Joint Replacement Registry (NJRR) (Web ref. 4), published in or prior to 2009 were included, as were manuscripts reporting on registry data and being published in 2009 and 2010. Osteoarthritis caused by femoroacetabular impingement is defined under primary osteoarthritis in most reports and the NJRR.

Table 2. Overview of the intermediate follow-up reports on HRA from the designer and non-designer centers.

Designer	Study design	HRA design (hybrid)	N hips (N pat) (N surg)	Indication	Age at surg (range)	Gender (% males)	FU y (range)	Kaplan-Meier (no sepsis) Time (y)	Revisions		Other survivorship (revision endpoint)	Other Reoperations	% Reoperations (revision + other)	Complic rate (% all)
									ALS/ALC/NOF/D/O	% NOF				
Amstutz et al., 2010	RS '96-'07	Conserve Plus	1107 (923) (1)	OA/RA/DDH/AVN/O	50 (14-78)	74%	6,8 (2,1 - 12,7)	5	26/NA/9/1/8	1	NA	NA	3,9	9,1
Daniel et al., 2004	RS 94-'01	McMinn (43)/BHR (403) (<55y)	446 (384) (1)	446/0/0/0/0	48 (27-55)	79%	3,3 (1,1-8,2)	4-7	1/0/0/0/0	0	0	0	0,2	0,2
Treacy et al., 2005	RS 97-'98	BHR	144 (130) (1)	125/2/3/10/4	87	NA	>5y (NA)	5	0/0/2/0/1	1,4	1	1	2,8	3,5
McBryde et al., 2008	RS 97-'04	BHR	96 (93) (8)	96/0/0/0/0	100	NA	4,5 (2,2-9,4)	5	0/0/0/0/0	0	0	0	0	0
McBryde et al., 2010	PS '97-'08	BHR	2123(1826)(26)	2123/0/0/0/0	100	62%	3,5 (0,03-10,9)	5	6/9/13/20	0,6	NA	NA	NA	2,3
Independent														
Back et al., 2005	PS '99-'01	BHR	230 (212) (3)	203/3/NA/12/10	88	66%	3 (2-4,4)		0/1/0/0/0	0	7	7	3,5	11
Hing et al., 2007							5 (4-6)		1/0/0/0/0	0	1	1	4,3^	12
Pollard et al., 2006	RS 99-'01	BHR	54 (51) (1)	42/0/3/4/5	78	78%	5 (4-6)		1/0/3/0/0	5,6	0	0	7,4	9,3
Steffen et al., 2008	RS 99-'06	BHR	610 (532) (7)	519/NA/57/18/16	85	59%	4,2 (2-8)	4 & 7	1/3/12/2/5	2	NA	NA	NA	3,8
		>5y FU	120 (107) (7)	110/NA/2/7/1	92	71%	5,3 (5-7,6)	5	0/0/2/1/2	1,7	NA	NA	NA	4
		<50y	231	13% DDH	78		<50	8			94%			
		>50y	379	7% DDH	90		>50	7			96%			
Heilpern et al., 2008	PS '99-'02	BHR	110 (98) (1)	97/3/4/4/2	88	58%	6 (5-7,5)	6	2/2/1(+1)/0/0	1,8	1	1	4,5	7,3
Olliviere et al., 2009	RS '01-'07	BHR	437 (437) (5)	NA	NA	66%	3,6 (0,5-9,0)	5	0/0/3/2/7	0,9	NA	NA	NA	2,9
Madhur et al., 2010	RS '99-'02	BHR	117 (101) (1)	NA	NA	58%	7 (5-9,4)	7	2/0/5/0/1	4,2	NA	NA	NA	17
								prim OA						
								sec OA						

This suggests that the results of the non-designer centers are good at 5 years and comparable to the NJRR results, but remain less optimal than those from the designer centers. cumulative % of reoperation

ALS: aseptic loosening stem

ALC: aseptic loosening cup

D: dislocations

O: other

Other survivorship: survivorship analysis evaluated without Kaplan-Meier and not taking reoperations into account

*not total female or males, but N SRA in females or males

° of all patients

FFU: final follow-up

Compl rate: overall reported complication rate, including complications not requiring surgery and revision surgery or any other reoperations

NA: not available

Therefore, in this report primary osteoarthritis was defined as osteoarthritis not related to (1) childhood hip joint degeneration such as hip dysplasia, Legg-Calve Perthes disease, (2) post-traumatic osteoarthritis, (3) osteonecrosis or other primary hip joint diseases.

Results

Failure of HRA

The outcome of HRA is determined by a complex interplay of patient-, implant- and surgery-related parameters. All these parameters can have different influences on the different failure modes of HRA. Femoral neck fractures, which have a prevalence of 1.0% to 5.6% (Beaulé *et al.*, 2004a; De Smet, 2005; Shimmin *et al.*, 2005a; Marker *et al.*, 2007; Steffen *et al.*, 2009b; Madhu *et al.*, 2010), and aseptic loosening, which has a prevalence of 1.0% to 2.0% (Beaulé *et al.*, 2004a), have been identified as the main causes of failure accounting for 75% of all aseptic revisions of HRA (Amstutz *et al.*, 2004b; Web ref. 1; Web ref 3). McBryde *et al.* (2010) found that the risk of revision was the highest in the first post-operative year and that periprosthetic fractures occurred in patients who were significantly older. This might suggest that bone quality plays an important role in HRA survival but there was no increased risk for fractures in females (Amstutz *et al.*, 2011; McBryde *et al.*, 2010). Refractive groin pain (6%) was another presumptive aseptic indication for HRA revision in Australia (de Steiger *et al.*, 2010). HRA appears to be associated with a higher prevalence of groin pain than conventional THA (18% versus 0.4-7%, respectively) (Ala Eddine *et al.*, 2001; O'Sullivan *et al.*, 2007; Bartelt *et al.*, 2010; Nasser *et al.*, 2010). Potential factors leading to groin pain include a proud anterior socket rim, neck-socket or iliopsoas impingement, hypersensitivity to metal ions, higher activity level and possibly higher expectations for patients receiving MoM bearing surfaces that might make those patients more likely to report postoperative pain (Taher and Power, 2003; Willert *et al.*, 2005; Korovessis *et al.*, 2006; O'Sullivan *et al.*, 2007; Khanduja and Villar, 2008). More recently, MoM related issues such as pseudotumors (Figs. 2 and 3), high blood ion levels and allergy towards Co-Cr ions have raised additional concerns against the use of HRA (Davies *et al.*, 2005; Willert *et al.*, 2005; Siebel *et al.*, 2006; De Haan *et al.*, 2008). Ollivere *et al.* (2009) reported a 1.9% incidence of metallosis as the indication for the early failure in a consecutive series of 493 Birmingham HRA. The prevalence of pseudotumours has been associated with female gender (Pandit *et al.*, 2008; Glyn-Jones *et al.*, 2009) but also component size is important because Amstutz *et al.* (2011) also found 4 cases all in patients with component sizes <46mm.

Revision of HRA is associated with a major risk of 5-year re-revision of 11%, which is much higher than the 2.8% revision risk of a primary THA (Web ref. 4). The cumulative re-revision rate of HRA is 8.4% at 3 years (Web ref. 4). This is comparable to the re-revision rate of conventional THA of 8.2% at 3 years (Web ref. 4). Socket-only revision is associated with a CRR of 20% at 5-years in comparison to 7% of femoral-only and 5% of both

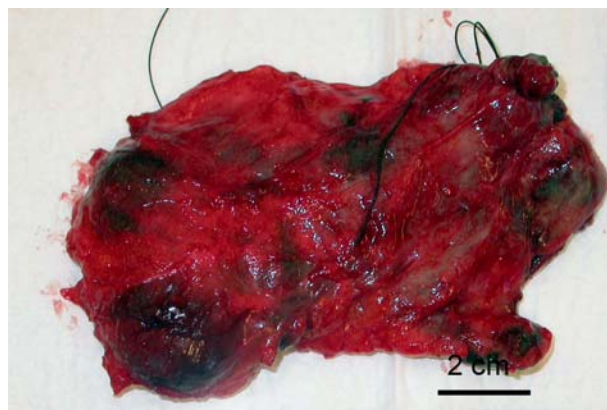


Fig. 2. Resected soft tissue mass around the posterolateral proximal femur (pseudotumor) in a 55-year old patient with a neck fracture 5 years following HRA.

component revisions (de Steiger *et al.*, 2010). Interestingly, infection is an uncommon cause of primary revision (0.3%) whereas 25% of re-revisions are conducted for infection (de Steiger *et al.*, 2010). Grammatopoulos *et al.* (2009) evaluated 53 HRA revisions and concluded that pseudotumors were associated with the highest risk of re-revision (38%).

Because of the clinical importance, the correlation between patient-, implant- and surgery-related parameters with the different failure modes of HRA will be discussed.

Patient related parameters

Initial studies indicated low failure rates at 1-7 years of follow-up. However, no comparison to age- and gender-matched cohorts following THA was provided (Table 2). This comparison was possible from the data provided in the NJRR (Corten and MacDonald, 2010; McGrory *et al.*, 2010). After adjustment for age and gender, HRA had a three- to fivefold increased risk for revision in comparison to THA in England, Wales and Sweden at 1 to 3 years (Web ref. 1; Web ref. 3). The overall 5-year cumulative percentage revision rate (CRR) of HRA was 3.7% as opposed to 2.7% for THA in Australia. This increased to 5.3% and 4%, respectively at 8 years and the lowest estimate of the additional risk for revision of HRA was 1.4 times compared to THA for matched patients during the first 7 years after surgery (McGrory *et al.*, 2010; Prosser *et al.*, 2010; Web ref. 4).

The indication for surgery, gender, component size and age have all been identified as important patient related prognosticators for HRA failure (Corten and MacDonald, 2010; McGrory *et al.*, 2010). Post-childhood hip disorders and avascular necrosis (AVN) were associated with a significantly higher risk of HRA failure compared to primary osteoarthritis (OA) and the 5-year revision risk of HRA for hip dysplasia (DDH) and AVN were respectively four and two times higher than that of THA (3%) (Web ref. 3; Web ref. 4). In general, male patients treated for primary OA had a 2.5 times lower risk of HRA failure than females, irrespective of age (McGrory *et al.*, 2010; Web ref. 3; Web ref. 4). However, this difference disappeared after adjustment for femoral component sizes ≥ 50 mm, which was in accordance to large case series

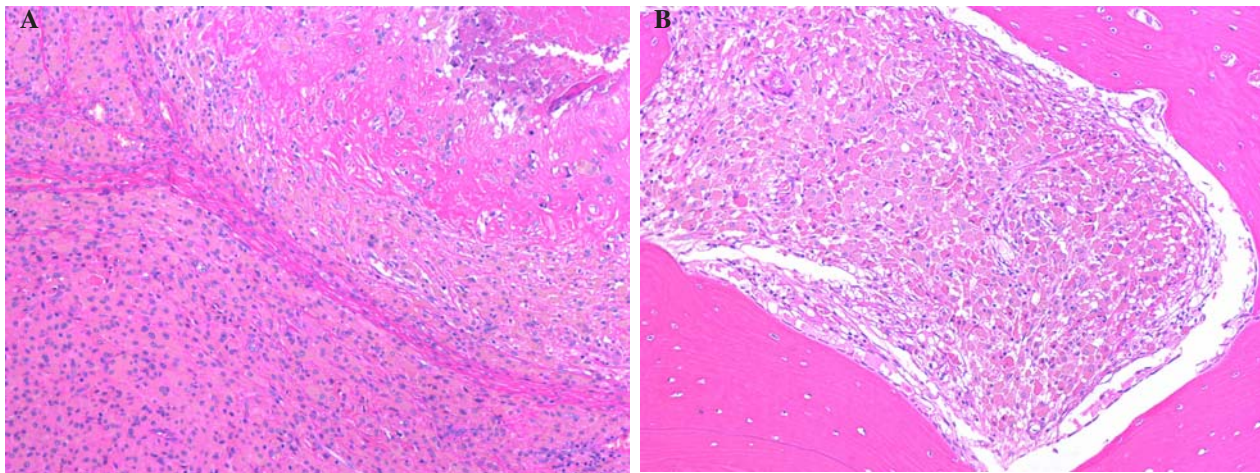


Fig. 3. The histological evaluation of the resected periarticular mass revealed an extensive macrophage infiltration of soft tissue (A) and bone (B) with accompanying sclerosis, fibrin depositis and focal necrosis (hematoxylin and eosin staining; original magnification 100x).

where the effect of gender was neutralized after stratifying to component size (Amstutz *et al.*, 2011; McBryde *et al.*, 2010). Moreover, within gender, the 5-year revision risk of HRA with head sizes ≥ 50 mm was comparable to THA (Prosser *et al.*, 2010; Web ref. 4). In addition, the risk for revision of components 44 mm and from 45 to 49 mm was respectively more than five- and threefold the risk for revision of components ≥ 55 mm in diameter (McGrory *et al.*, 2010). McBryde *et al.* (2010) found a 4.87-times increased risk of revision per year with every 4 mm decrease in femoral component size in a 5-year follow-up series of 655 cases. Finally, age was another important prognosticator with males < 65 years having slightly better results at 5 years with HRA than with THA (Web ref. 1; Web ref. 4). In females, however, a dramatic increase in revision rate was seen in those between 55 and 64 years indicating that females should be 55 years or younger at time of surgery (Prosser *et al.*, 2010; Web ref. 4). Probably less important prognosticators for failure are BMI and patient activity level as conflicting conclusions have been reported (Siebel *et al.*, 2006; Le Duff *et al.*, 2007; Amstutz *et al.*, 2011; Banerjee *et al.*, 2010). However, surgical bias towards these parameters should be taken into account. A higher sports activity level has not been found to be associated with adverse effects (Banerjee *et al.*, 2010) although others suggest that a BMI < 30 kg/m² and an increased activity level were interrelated which could explain the detrimental effect of a low BMI on survivorship (LeDuff *et al.*, 2007; Amstutz *et al.*, 2011). However, lower body weight has also been found to be associated with smaller component sizes (Beulé *et al.*, 2004a). Finally, a more normal morphology of the proximal femur and the absence of bone cysts > 1 cm have been associated with better outcomes (Amstutz *et al.*, 2004a; Beulé *et al.*, 2004a; Schmalzried *et al.*, 2005).

Implant related parameters

Metal-on-metal bearing surfaces have improved wear properties in comparison to conventional metal-on-polyethylene (MoPE) surfaces (MacDonald *et al.*, 2003). However, the size, the number and the chemical properties of released ion particles are different from the polyethylene

particles (Sieber *et al.*, 1999). As a consequence, the biologic responses to metal ions are different from those to MoPE (Davies *et al.*, 2005). The utilized implant has been identified as an important prognosticator for HRA failure (McGrory *et al.*, 2010; Web ref. 3; Web ref. 4). The Birmingham Hip Resurfacing (BHR) (Smith & Nephew, Memphis, TN, USA) was the most commonly used device (70%) with the longest follow-up in the NJRR (Web ref. 1; Web ref. 3; Web ref. 4). The 3-year revision rate was 1.8% in England and Wales (Web ref. 1). The number of revisions per 100 observed component years for the BHR was 0.8 as opposed to 2.6 and 2.3 for the ASR (DePuy, Warsaw, IN, USA) and Durom (Zimmer, Warsaw, IN, USA), respectively (Web ref. 4). There are 2 important features of an implant that determine the survivorship: metallurgy and implant design. Both are interrelated and determine the biological responses to implantation of a HRA.

Metallurgy

The metallurgy of the bearing surface is implant specific and is highly influenced by the manufacturing process. Briefly, the processes can be divided into cast- or wrought forged with hot isostatically pressed treatment or solution heat-treatment. This will result in different carbide contents that, in turn, determine the wear resistance and metal ion releases (Catelas *et al.*, 2003). A high carbon content wrought forged HRA design has been associated with the lowest metal ion releases (Vendittoli *et al.*, 2007). The biological responses to metal ion release can be divided into cellular, local and systemic reactions. Direct binding of Cr to cellular DNA is well documented (Wolf *et al.*, 1989) and will inhibit the repair processes of aberrant DNA (Witkiewicz-Kucharczyk and Bal, 2006). In addition, reactions with metal ions can lead to the generation of free radicals which can react with DNA and induce damage to purine and pyrimidine bases (Dizdaroglu *et al.*, 2002). They can also induce inter-strand crosslinks or DNA-protein crosslinks (Bacon *et al.*, 1983; Marnett, 1999). Permanent modification of genetic material resulting from this oxidative damage and the inhibition of the repair processes induced by Cr-bindings can represent the first

steps in mutagenesis and carcinogenesis. Focal chromosomal aberrations have been detected clinically (Ladon *et al.*, 2004) and concerns regarding the risk of carcinogenesis have raised (Gillespie *et al.*, 1996; Shimmin *et al.*, 2005b; Willert *et al.*, 2005; Keegan *et al.*, 2007; Lidgren, 2008). However, to date there is still no evidence that HRA would be associated with an increased risk for carcinogenesis. Various *local* adverse reactions, such as extensive necrosis (Boardman *et al.*, 2006; Ollivere *et al.* 2009), periprosthetic osteolysis (Amstutz *et al.*, 2011; von Schewelov and Sanzén, 2010) and soft tissue masses (pseudotumour reactions) (Figs. 2 and 3) (Gruber *et al.*, 2007; De Haan *et al.*, 2008; Hart *et al.*, 2009) have been associated with MoM devices. The underlying causes of these biological responses remain unclear, but are probably induced by an accumulation of abovementioned cellular responses to metal ion releases (Willert *et al.*, 2005; Davies *et al.*, 2005; Siebel *et al.*, 2006; De Haan *et al.*, 2008; Glyn-Jones *et al.*, 2009; Grammatopoulos *et al.*, 2009; Amstutz *et al.*, 2011; Campbell *et al.*, 2010). However, they have also been associated with a delayed immune reaction to metal ions (delayed hypersensitivity) (Pandit *et al.*, 2008). Campbell *et al.* (2010) demonstrated substantial differences in the histological features of pseudotumor-like tissues from patients with high wear compared with those tissues from patients suspected to have metal hypersensitivity. There was generally less disruption of the synovial surface, and greater preservation of the normal tissue architecture in the high wear group. In contrast, the most extensive damage to the tissues and the highest density of lymphocyte aggregates occurred in patients suspected to have a metal hypersensitivity reaction. Finally, pseudotumor-like reactions have also been reported in HRA without evidence of high wear or metal hypersensitivity (Malviya and Holland, 2009; Campbell *et al.*, 2010). The lesions can either be cystic or solid (Boardman *et al.*, 2006; Gruber *et al.*, 2007; Pandit *et al.*, 2008; Toms *et al.*, 2008; Grammatopoulos *et al.*, 2009) and are generally characterized by extensive necrosis in the presence of B-cells, T-lymphocytes, and plasma cells (Pandit *et al.*, 2008). The inflammatory blood markers remain normal. Periprosthetic osteolysis has also been associated with a perivascular accumulation of activated macrophages and T-lymphocytes producing bone-resorbing cytokines (Park *et al.*, 2005). In addition, Co and Cr are toxic to osteoblasts, leading to markedly reduced alkaline phosphatase activity (McKay *et al.*, 1996; Fleury *et al.*, 2006). The cells can also release pro-inflammatory cytokines such as IL-6 and TNF- α (Hallab, 2001; Anissian *et al.*, 2002; Hallab *et al.*, 2002). These cytokines can in turn activate the differentiation of pre-osteoclasts into mature bone resorbing cells (Kudo *et al.*, 2003). Finally, Co and Cr inhibit the release of osteocalcin into the bone matrix, thereby contributing to a delayed mineralization of the periprosthetic bone tissue (Morais *et al.*, 1998; Fernandes, 1999). A higher rate of hypersensitivity reactions to cobalt chloride skin testing was observed in patients with osteolysis, which suggested to be indicative for a delayed-type hypersensitivity to metal (Davies *et al.*, 2005; Park *et al.*, 2005). A vicious circle of phagocytosis, lysis and release of Co and Cr particles by the macrophages (Rae, 1986)

has been suggested to induce an acquired or antigen-specific immune response, such as a type IV delayed hypersensitivity reaction driven by T-lymphocytes (Hallab *et al.*, 2005; Willert *et al.*, 2005; Witzleb *et al.*, 2007). In addition, metal-protein complexes produced from degradation of metal alloys are immunologically active through unknown proliferative responses (Hallab, 2001). Unfortunately, there are currently no reliable standardized predictive tests for metal allergy and hypersensitivity (Shimmin *et al.*, 2008). There are some concerns regarding *systemic release* of the metal ions. Cobalt (Co) and chrome (Cr) ions are soluble. As a result, they are detectable in serum, erythrocytes and urine (MacDonald *et al.*, 2003; Back *et al.*, 2005; Daniel *et al.*, 2007; Daniel *et al.*, 2010). The peak serum levels of Co and Cr occurred at 6 and 9 months respectively, and reached a 10- and 16-fold increase, compared to the preoperative levels. These peaks were followed by a gradual decline over the next 15 months (Back *et al.*, 2005; Daniel *et al.*, 2007). There is evidence, from an animal study, to suggest that Cr ions can accumulate in the liver (Jakobsen *et al.*, 2007). In contrast, the renal Co clearance progressively increased at higher levels of Co release, thereby indicating that cumulative build-up of Co ions is not expected with normal kidney function – not even in cases of increased ions release (Daniel *et al.*, 2010). Increased transplacental ion levels have also been reported with concerns rising regarding the risk for chromosomal fetal aberrations (Case *et al.*, 1996; Doherty *et al.*, 2001; Ladon *et al.*, 2004; Brodner *et al.*, 2004; Papageorgiou *et al.*, 2007; Ziaee *et al.*, 2007). Finally, a combined Co and Cr whole blood level of >5 $\mu\text{g/L}$ was found to be associated with a reduction in the circulating levels of CD8+ lymphocytes. The clinical relevance of this observation remains unknown (Hart *et al.*, 2006).

Design

Some HRA implants might be more prone to metal ion release than others, because they have a specific design with a lower arc angle that can lead to more edge loading. This will jeopardize the lubrication and will lead to increased metal wear debris (De Haan *et al.*, 2008). There is a decreased femoral head-neck offset in HRA in comparison to THA. This leads to a higher risk for impingement of the femoral bone against the socket. Therefore, surgeons have to adjust the abduction or anteversion angle of the socket in order to prevent this impingement from occurring, but this adjustment might induce edge loading especially in those designs with a lower arc angle (De Haan *et al.*, 2008). In other words, when the arc angle (similar to the lateral center edge angle in native hips) is lower, there is a decreased window of opportunity to position the socket in an optimal position that does not induce impingement but also prevents edge-loading from occurring (Kluess *et al.*, 2008). These designs are thus more prone to increased metal debris and failure. Implant size influences the tribological behavior of HRA: higher ion levels have been found with smaller implants (Langton *et al.*, 2008). There might be several explanations. First, the sliding velocity is higher in larger implants and this enhances fluid-film lubrication (Smith

et al., 2001; Dowson *et al.*, 2004; Lin *et al.*, 2006; Liu *et al.*, 2006). Second, there might be less resistance to cup deformation in smaller implants. Third, the articular arc is smaller (Jeffers *et al.*, 2009) and therefore smaller cups are associated with an increased vulnerability to component malpositioning with undesirable socket abduction angles over 50-55°, which increases the risk of edge-related wear. Furthermore, smaller components are more likely to be used in mild or moderate DDH-cases which might lead to a steeper socket inclination as the shallower dysplastic acetabulae are more difficult to reconstruct. These situations will lead to less clearance and hence higher friction and wear of the articulating surface (De Haan *et al.*, 2008; Glyn-Jones *et al.*, 2009; Pandit *et al.*, 2008). In addition, smaller components may be more vulnerable to less optimal component positioning in the sagittal plane, as minor degrees of malalignment may lead to an increased risk of impingement because of the relative decrease in the head-neck ratio (Kluess *et al.*, 2008). Neck-socket impingement may lead to microseparation, rim damage and groin pain, eventually leading to revision surgery (Lavigne *et al.*, 2008b; Nikolaou *et al.*, 2009). Smaller diameter components might predispose to periprosthetic fractures because the femoral stem is often not proportionally sized, with the result that it is relatively thicker *versus* the femoral neck. This, in turn, leads to relatively more bone loss, increased superior neck strains and increased stress shielding due to a mismatch in the modulus of elasticity of the stem and the bone (Shimmin and Back, 2005; Shimmin *et al.*, 2005; Taylor, 2006; Radcliffe and Taylor, 2007; Appleyard *et al.*, 2008; Ong *et al.*, 2008).

Finally, the incidence of aseptic loosening of the socket seems to be implant-dependent with the BHR being associated with the lowest incidence at the present time (Table 2).

Surgery related parameters

Resurfacing is technically more difficult than conventional THA and each step in the procedure is subjected to surgical error starting from the surgical approach. Several case series indicate that improvement in technique and increased experience resulted in a decrease in revision rates and better functional outcome scores (Siebel *et al.*, 2006; Marker *et al.*, 2007; Mont *et al.*, 2007; Amstutz *et al.*, 2007; Amstutz *et al.*, 2011). However, this was not found in another large series (McBryde *et al.*, 2010). Surgery related parameters play an important role in implant survival on the femoral side. Zustin *et al.* (2010) analyzed a series of 107 femoral head remnants following fracture at a mean of 5 months after implantation. Three fracture morphologies with different causative explanations were identified. Acute non-necrotic fractures (9%) occurred outside the component and were likely provoked by mechanical weakening of the bone, induced by notching or uncovering of the bone, which is proportionally more important in smaller sizes. Acute post-necrotic fractures (52%) occurred at a mean of 5 months. Chronic non-necrotic fractures (40%) occurred at a mean of 6 months and might have been induced by factors such as varus positioning of the component or relative neck lengthening by abundant polar

cement (Zustin *et al.*, 2010). The latter can also predispose to aseptic loosening (Howie *et al.*, 1993). The cement mantle and depth of penetration vary widely, depending on the viscosity of the cement, the bone density and the design clearance between the reamed head and the femoral component (Mjoberg *et al.*, 1984; Chandler *et al.*, 2006; Morlock *et al.*, 2008; Shimmin *et al.*, 2010). The combination of a small component size and a low BMD could result in excessive penetration of cement thereby possibly leading to thermal necrosis of the femoral head. One study showed that loosening commonly occurred in the absence of AVN, and proposed that it may be related to local increase in pressure, abrasion by cement and interference with the local blood supply (Howie *et al.*, 1993). The following relevant surgery-related parameters of the HRA procedures will therefore be discussed: (1) parameters leading to neurovascular injuries, (2) bone conservation on the acetabular side, (3) femoral component positioning and (4) cementing techniques. The importance of accurate acetabular component positioning to prevent edge loading and increased surface wear has been discussed above.

Neurovascular injuries

Post-operative avascular necrosis of the femoral head has been suggested to be one of the reasons for a periprosthetic fracture, neck narrowing or loosening following HRA (Schimmin and Back, 2005a; Beaulé *et al.*, 2006b; Zustin *et al.*, 2010). The understanding of the anatomy of the extraosseous blood supply to the femoral head is of particular interest when conducting HRA because of its vulnerability during the procedure, especially with the most commonly used extended posterolateral approach (Gautier *et al.*, 2000; Steffen *et al.*, 2005; Beaulé *et al.*, 2006a; Beaulé *et al.*, 2007a; Khan *et al.*, 2007; Amarasekera *et al.*, 2008). Several approaches have been investigated or modified in order to preserve an optimal oxygenation of the femoral head during and after the procedure. The direct lateral approach (Nork *et al.*, 2005; Jacobs *et al.*, 2008), the trochanteric flip approach according to Ganz *et al.* (Ganz *et al.*, 2001; Steffen *et al.*, 2009a), and the modified posterolateral approach (Steffen *et al.*, 2010) have all been shown to lead to less disruption of the blood flow and oxygenation of the femoral head in comparison to the extended posterolateral approach which was associated with a decrease of the blood flow, ranging from 40% to 70% (Beaulé *et al.*, 2007a; Khan *et al.*, 2007; Amarasekera *et al.*, 2008). However, the consequences of the disruption of the medial femoral circumflex artery (Gautier *et al.*, 2000; Kalhor *et al.*, 2009), with the development of osteonecrosis, remains unproven (Freeman, 1978; Hananouchi *et al.*, 2010) – possibly because of the variability in vascularization and/or the proposed presence of an intraosseous blood supply, which can be increased in osteoarthritic joints (Whiteside *et al.*, 1983). The latter has not been confirmed by recent studies (Schoeniger *et al.*, 2009a). Smaller femoral head sizes can be more vulnerable to disruption of the extra- and intra-osseous blood supply (Steffen *et al.*, 2005), especially due to the danger of notching and particularly when the stem sizes are not proportional to the femoral neck diameter. The risk

for other neurovascular injuries could be minimized. It was shown, in a cadaver study, that the highest pressures experienced by the sciatic nerve occurred during acetabular exposure through the posterolateral approach when the femur was retracted anteriorly. These pressures dropped once the gluteal sling, which is the extension of the gluteal maximus tendinous insertion, was released (Gay *et al.*, 2010). Another cadaver study demonstrated that the anterior capsule should be released after dislocation and with the hip flexed, as all 3 femoral neurovascular structures move away from the anterior capsule in that position (Davis *et al.*, 2010).

Acetabular bone preservation

There is some concern that more acetabular bone is removed with HRA (Loughead *et al.*, 2006). This is the reason why some surgeons try to downsize the femoral component as much as possible thereby increasing the risk of notching with disrupting the blood supply and neck/socket impingement. However, other studies have shown that the acetabular component size in HRA is comparable to cementless THA (Venditelli *et al.*, 2006; Moonot *et al.*, 2007; Brennan *et al.*, 2009; Naal *et al.*, 2009). There are no data available whether the pelvic bone stock would be compromised for revision surgery of HRA. Therefore, we consider it to be advisable not to downsize the femoral component and adjust the socket size to the femoral component size.

Component positioning

Finite element analysis and biomechanical studies have suggested that 10° of relative valgus can increase the failure load and reduce the local bone strains and cement stresses associated with early femoral component failure (Long and Bartel, 2006; Anglin *et al.*, 2007). On the other hand, excessive valgus malpositioning may produce notching of the femoral neck and consequently may increase the risk of fracture (Beaulé *et al.*, 2006b). Therefore, some authors have suggested that the instrumentation should be improved or to use computed navigation, which has been shown to give a more accurate and less variable femoral component placement (Davis *et al.*, 2007).

Cementing technique

The cementing technique might be an important factor for long-term survival, especially in smaller components. It has been proposed that the reduced surface area for cement fixation of smaller femoral components compromises long-term femoral fixation (Amstutz *et al.*, 2011). Therefore, it was recommended that additional drill holes should be made in the prepared femoral head to increase the fixation area (McBryde *et al.*, 2010). Despite that this was done in all procedures, in a large series of 655 cases with more than 5 years follow-up, smaller component sizes were still associated with increased failure rates – leading the authors to suggest that factors other than the cementing technique might play a role in the higher failure rates of smaller components (McBryde *et al.*, 2010). Moreover, drilling cement holes in smaller heads will be done with smaller distances between the holes possibly leading to more thermal necrosis. Cement penetration of 3 to 4 mm is

required to engage at least one level of transverse trabeculae with sufficient filling of the vertical channels (Walker *et al.*, 1984). The insertion of a suction device into the lesser trochanter, pulse lavage of the head, debridement of the cysts and a dome hole suction have been suggested not only to optimize cement penetration (Amstutz *et al.*, 2007), but also to decrease the risk of thermal necrosis when early reduction is performed (Gill *et al.*, 2007). However, too deep cement penetration should be avoided, in order to decrease the risk of thermal necrosis (Campbell *et al.*, 2006). Applying low viscosity cement to the femoral component, with an indirect filling technique, has been shown to lead to polar region cement concentration with deep radial cement penetration and a significant lack of cement at the head-neck junction site (Scheerlinck *et al.*, 2010). The most homogenous distribution of cement around the femoral head with a uniform penetration of maximum 4 mm could be achieved with high viscosity cement applied directly onto the femoral bone (Falez *et al.*, 2010). In accordance, Scheerlinck *et al.* (2010) found that the cement mantle was more closely to the desired goal of 3 mm thickness with direct cement packing. In addition, they found that with direct cement packing and six anchoring holes, of 4.5 mm in diameter and 4 mm in depth, there was no major effect on the amount of cement pressurized into the bone – which would minimize local exothermic polymerization reactions. However, cement packing caused a higher prevalence of interfacial gaps in the proximal two-thirds of the implant, a finding of which the consequences were not clear to the authors (Scheerlinck *et al.*, 2010).

Functional outcomes and quality of life following

HRA

Patients treated with HRA have been noted to have high postoperative activity levels and quality of life scores (Narvani *et al.*, 2006; Naal *et al.*, 2007), which are higher than those of their THA counterparts (Pollard *et al.*, 2006; Vail *et al.*, 2006; Lavigne *et al.*, 2008a; Mont *et al.*, 2009) – even after adjustments for pre-operative activity levels (Zywiell *et al.*, 2009). One study reported that more HRA patients returned to work (96%) and heavy to moderate activities (72%) 1 year postoperatively than THA patients (66% and 39%, resp.). However, both groups were not completely comparable as the mean BMI of the HRA group was significantly lower (Lilikakis *et al.*, 2005). Gender influences functional outcome scores as Amstutz *et al.* found, in a case series of 923 patients, that women improved more in walking, function, and the SF-12 mental component, whereas males improved more in activity at an average follow-up of 7 years (Amstutz *et al.*, 2011). Others found a high level of sports activities after HRA surgery, with older patients being more active than younger patients (Naal *et al.*, 2007). More patients participated more frequently in sports activities with a longer duration of activities following HRA (Narvani *et al.*, 2006; Banerjee *et al.*, 2010). However, there was a decrease in high-impact activities with an increase in low-impact activities found in another survey of 138 patients at a mean of 2 years post-operatively (Banerjee *et al.*, 2010). Several complaints were reported, such as pain (5.9%), fear (4.6%), decreased

strength and endurance (5.9%), and a limited range of motion (5.3%) (Banerjee *et al.*, 2010). Bozic *et al.* (2010) used a Markov decision model to evaluate the clinical and economic consequences of HRA compared to THA, in the United States, and concluded that over a 30-year follow-up period, HRA patients would experience modestly higher lifetime gains in quality adjusted life years – with moderately higher health care costs compared to THA patients. However, the cost-effectiveness varied markedly by age and gender with lower incremental cost-effectiveness ratios in men compared to women and in younger patients compared to older patients.

HRA can improve terminal flexion by 17° to 32° over the preoperative values (Schmalzried *et al.*, 2005; Vail *et al.*, 2006; Banerjee *et al.*, 2010). However, Incavo *et al.* (2010) have shown, in a cadaver study, that there were significant deficiencies with 2 (25%) hips having deficits in extension and 7 (88%) having deficits in flexion – which were both normal with THA (Incavo *et al.*, 2010). Osteochondroplasty of the resurfaced neck was not considered in these HRA procedures, whereas a decreased head-neck offset has been associated with a lack of flexion (Doherty *et al.*, 2007; Kluess *et al.*, 2008). With a typical resurfacing component, a head-to-neck ratio of 1.4 should be achieved and some surgeons even consider femora with a head-neck ratio less than 1.2 to be unfavorable for resurfacing (McCabe *et al.*, 1999; Schmalzried *et al.*, 2005). Osteochondroplasty could be used to attempt to create an ideal head-neck offset (Beaulé *et al.*, 2007b), but this can sometimes be difficult to achieve in HRA (Malik *et al.*, 2007) and then proper cup orientation becomes more important to optimize the range flexion (Herrlin *et al.*, 1988; Barrack, 2003; Seki *et al.*, 1998). Malviya *et al.* (2010) found, in a series of 82 HRA, that socket anteversion was more strongly associated with hip flexion than cup abduction or head-neck offset. Little is known about the lack of restoration of leg length discrepancies in HRA. One study has shown that 42% of patients had a limb-length discrepancy after surgery in comparison to 23% pre-operatively (Banerjee *et al.*, 2010).

Complications, not directly leading to revision surgery, have been noted with the incidence of nerve palsies being between 1.7% and 2.1%, which is higher than in THA (1%) (Schmalzried *et al.*, 1997; Hing *et al.*, 2007; Della Valle *et al.*, 2009; Madhu *et al.*, 2010). Injury to the femoral neurovascular structures after hip resurfacing is rare (0.25% to 1.3%), if proper instrumentation is being used (Back *et al.*, 2005). Squeaking has been reported in short-term episodes with the incidence ranging from 3.4% to 10%. This could not be related to decreased patient satisfaction (Ebied and Journeaux, 2002; Back *et al.*, 2005; Hing *et al.*, 2007; Esposito *et al.*, 2010). Clicking has been reported with a prevalence of 1.6% (Madhu *et al.*, 2010).

Discussion

Concerns regarding high rates of THA failure among young, active patients and a desire to preserve bone for future revision procedures, has led to the development of hip resurfacing arthroplasty – which was first introduced

in the United States in the 1970s (Amstutz *et al.*, 1986; Schmalzried *et al.*, 1994). However, early clinical experience with HRA was unfavorable, as high failure rates of aseptic loosening were reported (Head, 1981; Bell *et al.*, 1985; Mont *et al.*, 1999). The procedure fell out of favor among orthopedic surgeons in the late 1980s (Jolley *et al.*, 1982; Bell *et al.*, 1985). The reemergence of the resurfacing concept was caused by the development of manufacturing processes that allowed the production of more optimal metal bearing surfaces since the 1990s. The initial single center reports supported favorable and promising outcomes with HRA (Table 2), however there is a lack of multicenter scrutiny of this procedure. It is the merit of national joint replacement registries that large cohorts of patients could be followed and prognosticators for failure could be identified and compared to conventional THA, which remains the gold standard for hip replacement. Overall, this comparison is not in favor of HRA. However, detailed evaluation of the results showed that the results should be nuanced. Even more, under stringent criteria HRA was associated with improved outcome in comparison to THA.

Patients undergoing HRA are active in sports and would like to take up sports again after the procedure (Wylde *et al.*, 2008). It appears realistic to allow patients to regain their active lifestyle following HRA, although it can be anticipated that not all strenuous sport activities will be resumed. Moreover, HRA has been associated with improved cost-effectiveness in the long term, especially in young, male patients. These advantages are of importance for this young patient population, but prognosticators that are associated with early failure or unfavorable functional outcome should be addressed.

Despite careful laboratory testing, certain implant designs resulted in premature failure (McGrory *et al.*, 2010; Web ref. 3; Web ref. 4). When the orthopedic community at large is considered, the results from highly specialized centers may be misleading and perhaps overly optimistic as indicated by the NJRR. Based on the registry data, HRA is associated with less optimal results than THA at 5 to 8 years. The lowest estimate of the additional risk for revision of HRA, compared to THA, was 1.4 times for matched patients during the first 7 years after surgery (McGrory *et al.*, 2010; Web ref. 4). However, these findings should be nuanced as the surgical techniques, implant designs and results are still evolving. Moreover, in depth analysis of the registry data and long-term case series allowed us to isolate prognosticators for implant failure. Briefly, the most important patient related factors are secondary osteoarthritis as the indication for surgery such as post-childhood hip disorders or AVN, female gender, smaller component sizes and older age (>65 years for males and >55 years for females). In addition, surgical technique (approach and cementing technique) and component design were also important determinant factors for the risk of failure. Rather than vilifying the HRA concept, one should use this knowledge to improve the techniques and narrow the indications for HRA thereby probably optimizing the intermediate and long-term results.

The concept of HRA as a bone conservative procedure needs also to be applied to the soft tissues. Any

conventional approach, whether it is posterolateral or direct lateral, bears the risk of violating important soft tissues such as muscles or neurovascular structures around the hip. This is the reason why some surgeons utilize the trochanteric flip technique, with the modification of creating a step-osteotomy (Schoeniger *et al.*, 2009b) of the greater trochanter instead of a flat osteotomy (Beaulé *et al.*, 2009). This technique is well established and is frequently used to treat young adults with femoro-acetabular impingement (Ganz *et al.*, 2001). It has been shown to preserve the blood supply of the femoral head and it minimizes any damage to the peri-articular muscles. In addition, the technique allows for the obtaining of an optimal visualization of the acetabulum, with a minimum risk of neurovascular injuries with external instead of internal rotation of the hip for femoral and acetabular preparation, which might be beneficial to minimize the risk of sciatic nerve injuries. The trochanter step osteotomy, with a ridge of the anterior cortex and step cut provides additional stability to the mobile trochanter fragment in the cranio-caudal and antero-posterior directions. The personal experience of one of the senior authors (M. Leunig, personal communication), with this technique using over 100 BHR resurfacing implants, showed that there was no avascular necrosis, fractures or trochanter non-unions at a follow-up of 1 to 4 years. There were few trochanter refixations (< 5%) due to trochanter displacements and trochanter screws had to be removed in about 25% of cases. After insertion of the implants, we routinely conduct an osteochondroplasty in case impingement of the neck would occur on the acetabular rim. Socket reorientation can be done in case the osteochondroplasty, but would have to be too extensive to optimize flexion. These measures will minimize the risk for groin pain and optimize the ROM of the hip. Post-operatively, the patients are held on crutches for 6 weeks partial weight bearing which would allow for trochanter healing and also neck healing following the osteochondroplasty.

Component size as a prognosticator has been shown to be more important than gender. There may be a threshold proportion below which a THA should be considered. Some authors feel it should be 48 mm or ≤ 42 mm (Amstutz *et al.*, 2011; McBryde *et al.*, 2010), but based on the registry data we feel a threshold of 50 mm seems more prudent, certainly for less experienced surgeons. Female gender does not seem to be a contra-indication for HRA (Amstutz *et al.*, 2011; McBryde *et al.*, 2010; Prosser *et al.*, 2010). However, the outcomes of HRA in females are more dependent and vulnerable to other prognosticators such as age (<55 years), diagnosis (higher prevalence of DDH in women) and smaller component sizes. The latter two are more frequently found in female patients (83% size < 50mm). Also, the adaptations of surgical techniques have been shown to more significantly improve the HRA outcomes in females than in males (Amstutz *et al.*, 2011). The place of pre-operative DEXA scans as a diagnostic tool in females remains to be clarified. Therefore, we feel that the indications for HRA should be even more stringent in females than in males.

Although the effect of component size on intermediate to long-term survivorship is most likely multifactorial, it remains uncertain what the most important pathophysiological mechanism is leading towards these adverse events. Analysis of the currently used cementing techniques has shown that there are possibilities for improvement that might optimize the survival of the implants. Direct cement packing on the prepared bone leads to the most reproducible and best cement mantle thickness and does not increase cement penetration into the bone at the site of the additional drill holes. Furthermore, it decreases the risk for incomplete seating due to an oversized polar cement mantle thickness. These features minimize the risk for thermal necrosis. In addition, this risk might also be minimized if design modifications with proportional stem sizes in smaller components would be available. Finally, computer navigation can be used and is advisable in less experienced hands.

There is a broad choice of more than 10 resurfacing prostheses currently available in Europe. These devices have subtle differences in design, in terms of material composition, dimensions of the stem, geometry and fixation – all of which have a role in the performance of the device. As a result, some devices have been associated with significantly higher risks of failure than others. Therefore, we believe that risk factors of these designs should be carefully identified, evaluated and improved upon. In addition, the design features of all currently available designs should be optimized to decrease the risk of edge loading, anterior over coverage of the rim and fixation to the bone. This will allow hip resurfacing to be used, with more reliable results, by the orthopedic community at large. Also, advanced research of different bearing surfaces should lead to surfaces that are not associated with concerns regarding adverse events, such as metal hypersensitivities or trans-placental increased metal-ion levels. However, correct placement of the components will remain a crucial prognosticator for the success of the procedure, regardless of which bearing will be used.

Interestingly, the presumed ease of femoral-only revision cannot be extrapolated into a better outcome since the 5-year CRR of femoral-only revision (7%) was over twice the risk of revision of primary THA. In addition, the risk for re-revision following HRA was much higher than the risk for revision following conventional THA. Therefore, it is of paramount importance that as many risk factors as possible for failure of HRA are being neutralized in order to optimize the outcomes of this attractive hip replacement concept that can be used to treat young and active patients.

Acknowledgements

The authors thank Dr. Beata Bode-Lesniewska of the Institute of Surgical Pathology, University Hospital, Zurich, for the outstanding support and advice concerning the pathologic findings of pseudotumors in metal-on-metal hip replacements. The authors declare no conflicting interests.

References

- Ala Eddine T, Remy F, Chantelot C, Giraud F, Migaud H, Duquenois A (2001) Anterior iliopsoas impingement after total hip arthroplasty: diagnosis and conservative treatment in 9 cases [in French]. *Rev Chir Orthop Reparatrice Mot* **87**: 815-819.
- Amarasekera HW, Costa ML, Foguet P, Krikler SJ, Prakash U, Griffin DR (2008) The blood flow to the femoral head/neck junction during resurfacing arthroplasty: a comparison of two approaches using laser doppler flowmetry. *J Bone Joint Surg (Br)* **90**: 442-445.
- Amstutz HC, Thomas BJ, Jinnah R, Kim W, Grogan T, Yale C (1984) Treatment of primary osteoarthritis of the hip. A comparison of total joint and surface replacement arthroplasty. *J Bone Joint Surg (Am)* **66**: 228-241.
- Amstutz HC, Dorey E, O'Carroll PF (1986) THARIES resurfacing arthroplasty, evolution and long-term results. *Clin Orthop Relat Res* **213**: 92-114.
- Amstutz HC, Grigoris P, Dorey FJ (1998) Evolution and future of surface replacement of the hip. *J Orthop Sci* **3**: 169-186.
- Amstutz HC, Beaulé PE, Dorey FJ, LeDuff M, Campbell P, Gruen T (2004a) Metal-on-metal hybrid surface arthroplasty: two to six year follow-up. *J Bone Joint Surg (Am)* **86**: 28-39.
- Amstutz HC, Campbell PA, Le Duff MJ (2004b) Fracture of the neck of the femur after surface arthroplasty of the hip. *J Bone Joint Surg (Am)* **86**: 1874-1877.
- Amstutz HC, Su EP, Le Duff MJ (2005) Surface arthroplasty in young patients with hip arthritis secondary to childhood disorders. *Orthop Clin North Am* **36**: 223-230.
- Amstutz HC, Le Duff MJ, Campbell PA, Dorey FJ (2007), The effects of technique changes on aseptic loosening of the femoral component in hip resurfacing, Results of 600 Conserve Plus with a 3 to 9 year follow-up. *J Arthroplasty* **22**: 481-489.
- Amstutz HC, Wisk LE, Le Duff MJ (2011) Sex as a patient selection criterion for metal-on-metal hip resurfacing arthroplasty. *J Arthroplasty* **26**: 198-208.
- Anglin C, Masri BA, Tonetti J, Hodgson AJ, Greidanus NV (2007) Hip resurfacing femoral neck fracture influenced by valgus placement. *Clin Orthop Rel Res* **465**: 71-79.
- Anissian L, Stark A, Dahlstrand H, Granberg B, Good V, Bucht E (2002) Cobalt ions influence proliferation and function of human osteoblast-like cells. *Acta Orthop Scand* **73**: 369-374.
- Appleyard RW, Walter W, Walter L, Ektas N, Gillies RM (2008) The influence of femoral head resurfacing on femoral neck strain: a biomechanical study. Proceedings 9th EFORT Congress, 2008.
- Back DL, Dalziel R, Young D, Shimmin A (2005) Early results of primary Birmingham hip resurfacings. An independent prospective study of the first 230 hips, *J Bone Joint Surg (Br)* **87**: 324-329.
- Bacon BR, Tavill AS, Brittenham GM, Park CH, Recknagel RO (1983) Hepatic lipid peroxidation *in vivo* in rats with chronic iron overload. *J Clin Invest* **71**: 429-439.
- Ball ST, Le Duff MJ, Amstutz HC (2007) Early results of conversion of a failed femoral component in hip resurfacing arthroplasty. *J Bone Joint Surg (Am)* **89**: 735-741.
- Banerjee M, Bouillon B, Banerjee C, Balthis H, Lefering R, Nardini M, Schmidt J (2010) Sports activity after total hip resurfacing. *Am J Sports Med* epub ahead 2010.
- Barrack RL (2003) Dislocation after total hip arthroplasty: implant design and orientation. *J Am Acad Orthop Surg* **11**: 89-99.
- Bartelt RB, Yuan BJ, Trousdale RT, Sierra RJ (2010) The prevalence of groin pain after metal-on-metal total hip arthroplasty and total hip resurfacing. *Clin Orthop Relat Res* **468**: 2346-2356.
- Beaulé PE, Dorey FJ, LeDuff M, Gruen T, Amstutz HC (2004a) Risk factors affecting outcome of metal-on-metal surface arthroplasty of the hip. *Clin Orthop Relat Res* **418**: 87-93.
- Beaulé PE, Le Duff M, Campbell P, Dorey FJ, Park SH, Amstutz HC (2004b) Metal-on-metal surface arthroplasty with a cemented femoral component. A 7-10 year follow-up study. *J Arthroplasty* **19 (Suppl 3)**: S17-22.
- Beaulé PE, Campbell PA, Lu Z, Leunig-Ganz K, Beck M, Leunig M, Ganz R (2006a) Vascularity of the arthritic femoral head and hip resurfacing. *J Bone Joint Surg (Am)* **88**: 85-96.
- Beaulé PE, Campbell PA, Hoke R, Dorey F (2006b) Notching of the femoral neck during resurfacing arthroplasty of the hip: a vascular study. *J Bone Joint Surg (Br)* **88**: 35-39.
- Beaulé PE, Campbell PA, Shim P (2007a) Femoral head blood flow during hip resurfacing. *Clin Orthop Rel Res* **456**: 148-52.
- Beaulé PE, Harvey N, Zaragoza E, Le Duff MJ, Dorey FJ (2007b) The femoral head/neck offset and hip resurfacing. *J Bone Joint Surg (Br)* **89**: 9-15.
- Beaulé PE, Shim P, Banga K (2009) Clinical experience of Ganz surgical dislocation approach for metal-on-metal hip resurfacing. *J Arthroplasty* **24(Suppl)**: S127-131.
- Bell RS, Schatzker J, Fornasier VL, Goodman SB (1985) A study of implant failure in the Wagner resurfacing arthroplasty. *J Bone Joint Surg (Am)* **67**: 1165-1175.
- Boardman DR, Middleton FR, Kavanagh TG (2006) A benign psoas mass following metal-on-metal resurfacing of the hip. *J Bone Joint Surg (Br)* **88**: 402-404.
- Bozic KJ, Pui CM, Ludeman MJ, Vail TP, Silverstein MD (2010) Do the potential benefits of metal-on-metal hip resurfacing justify the increased cost and risk of complications. *Clin Orthop Rel Res* **468**: 2301-2312.
- Brennan SA, Harty JA, Gormley C, O'Rourke SK (2009) Comparison of acetabular reamings during hip resurfacing versus uncemented total hip arthroplasty. *J Orthop Surg (Hong Kong)* **17**: 42-46.
- Brodner W, Grohs JG, Bancher-Todesca D, Dorotka R, Meisinger V, Gottsauner-Wolf F, Kotz R (2004) Does the placenta inhibit the passage of chromium and cobalt after metal-on-metal total hip arthroplasty? *J Arthroplasty* **19**: 102-106.
- Campbell P, Beaulé PE, Ebramzadeh E, Le Duff M, De Smet K, Lu Z, Amstutz HC (2006) A study of implant

failure in metal-on-metal surface arthroplasties. *Clin Orthop Relat Res* **453**: 35-46.

Campbell P, Ebramzadeh E, Nelson S, Takamura K, De Smet K, Amstutz AC (2010) Histologic features of pseudotumour-like tissues from metal-on-metal hips. *Clin Orthop Relat Res* **468**: 2321-2327.

Capello WN, Trancik TM, Misamore G, Eaton R (1982) Analysis of revision surgery of resurfacing hip arthroplasty. *Clin Orthop Relat Res* **170**: 50-55.

Case CP, Langkamer VG, Howell RT, Webb J, Standen G, Palmer M, Kemp A, Learmonth ID (1996) Preliminary observations on possible premalignant changes in bone marrow adjacent to worn total hip arthroplasty implants. *Clin Orthop Rel Res* **329**: S269-279.

Catelas I, Bobyn JD, Medley JB, Krygier JJ, Zukor DJ, Huk OL. (2003) Size, shape, and composition of wear particles from metal-metal hip simulator testing: effects of alloy and number of loading cycles. *J Biomed Mater Res A*. **67**: 312-327.

Chandler M, Kowalski RS, Watkins ND, Briscoe A, New AM (2006) Cementing techniques in hip resurfacing. *Proc Inst Mech Eng [H]* **220**: 321-331.

Corten K, MacDonald SJ (2010) Hip resurfacing data from national joint registries: What do they tell us? What do they not tell us. *Clin Orthop Relat Res* **468**: 351-357.

Crawford JR, Palmer SJ, Wimhurst JA, Villar RN (2005) Bone loss at hip resurfacing: a comparison with total hip arthroplasty. *Hip Int* **15**: 195-198.

Daniel J, Pynsent PB, McMinn DJ (2004) Metal-on-metal resurfacing of the hip in patients under the age of 55 years with osteoarthritis. *J Bone Joint Surg (Br)* **86**: 177-184.

Daniel J, Ziaee H, Pynsent PB, McMinn DJ (2007) The validity of serum levels as a surrogate measure of systemic exposure to metal ions in hip replacement. *J Bone Joint Surg (Br)* **89**: 736-741.

Daniel J, Ziaee H, Pradhan C, Pynsent PB, McMinn DJ (2010) Renal clearance of cobalt in relation to the use of metal-on-metal bearings in hip arthroplasty. *J Bone Joint Surg (Am)* **92**: 840-845.

Davies AP, Willert HG, Campbell PA, Learmonth ID, Case CP (2005) An unusual lymphocytic perivascular infiltration in tissues around contemporary metal-on-metal joint replacements. *J Bone Joint Surg (Am)* **87**: 18-27.

Davis ET, Gallie PA, Macgroarty K, Waddell JP, Schemitsch E (2007) The accuracy of image-free computer navigation in the placement of the femoral component of the Birmingham hip resurfacing: a cadaver study. *J Bone Joint Surg (Br)* **89**: 557-560.

Davis ET, Gallie PA, James SL, Waddell JP, Schemitsch EH (2010) Proximity of the femoral neurovascular bundle during hip resurfacing. *J Arthroplasty* **3**: 471-474.

De Haan R, Campbell PA, Su EP, De Smet KA (2008) Revision of metal-on-metal resurfacing arthroplasty of the hip: the influence of malpositioning of the components. *J Bone Joint Surg (Br)* **90**: 1158-1163.

De Smet KA (2005) Belgium experience with metal-on-metal surface arthroplasty. *Orthop Clin North Am* **36**: 203-213.

De Smet KA, Pattyn C, Verdonck R (2002) Early results of primary Birmingham hip resurfacing using a hybrid metal-on-metal couple. *Hip Int* **12**: 158-162.

de Steiger RN, Miller LN, Prosser GH, Graves SE, Davidson DC, Stanford TE (2010) Poor outcome of revised resurfacing hip arthroplasty, 397 cases from the Australian Joint Replacement Registry. *Acta Orthop* **81**: 72-76.

Della Valle CJ, Nunley RM, Raterman SJ, Barrack RL (2009) Initial American experience with hip resurfacing following FDA approval. *Clin Orthop Relat Res* **467**: 72-78.

Dizdaroglu M, Jaruga P, Birincioglu M, Rodriguez H (2002) Free radical-induced damage to DNA: mechanisms and measurement. *Free Radic Biol Med* **32**: 1102-1115.

Doherty AT, Howell RT, Ellis LA, Bisbinas I, Learmonth ID, Newson R, Case CP (2001) Increased chromosome translocations and aneuploidy in peripheral blood lymphocytes of patients having revision arthroplasty of the hip. *J Bone Joint Surg (Br)* **83**: 1075-1081.

Doherty S, Thompson M, Usrey M (2007) Does hip resurfacing restore normal range of motion and provide better joint motion than THR? Transactions from the 53rd Annual Meeting of the Orthopaedic Research Society. San Diego, CA (Paper 0276).

Dowson D, Hardaker C, Flett M, Isaac GH (2004) A hip joint simulator study of the performance of metal-on-metal joints, Part II: design. *J Arthroplasty* **19**: 124-130.

Ebied E, Journeaux SF (2002) Metal-on-metal hip resurfacing. *Curr Orthop* **16**: 420-425.

Esposito C, Walter WL, Campbell P, Roques A (2010) Squeaking in metal-on-metal hip resurfacing arthroplasties. *Clin Orthop Relat Res* epub ahead 2010.

Falez F, Favetti F, Casella F, Papalia M, Panegrossi G (2010) Patterns of cement distribution in total hip resurfacing arthroplasty. *J Arthroplasty* epub ahead 2010.

Fernandes MH (1999) Effect of stainless steel corrosion products on *in vitro* biomineralization. *J Biomater Appl* **14**: 113-168.

Fleury C, , Petit A, Mwale F, Antoniou J, Zukor DJ, Tabrizian M, Huk OL (2006) Effect of cobalt and chromium ions on human MG-63 osteoblasts in vitro: morphology, cytotoxicity, and oxidative stress. *Biomaterials* **27**: 3351-3360.

Freeman MA (1978) Some anatomical and mechanical considerations relevant to the surface replacement of the femoral head. *Clin Orthop Rel Res* **134**: 19-24.

Freeman MA, Bradley GW (1983) ICLH surface replacement of the hip. An analysis of the first 10 years. *J Bone Joint Surg (Br)* **65**: 405-411.

Ganz R, Gill TJ, Gautier E, Ganz K, Krugel N, Berlemann U (2001) Surgical dislocation of the adult hip: a technique with full access to the femoral head and acetabulum without the risk of avascular necrosis. *J Bone Joint Surg (Br)* **83**: 1119-1124.

Gautier E, Ganz K, Krugel N, Gill T, Ganz R (2000) Anatomy of the medial femoral circumflex artery and its surgical implications. *J Bone Joint Surg (Br)* **82**: 679-683.

Gay DP, Desser DR, Parks BG, Boucher HR (2010) Sciatic nerve injury in total hip resurfacing. *J Arthroplasty* epub ahead 2010.

- Gill HS, Campbell PA, Murray DW, De Smet KA (2007) Reduction of the potential for thermal damage during hip resurfacing. *J Bone Joint Surg (Br)* **89**: 16-22.
- Gillespie WJ, Henry DA, O'Connell DL, Kendrick S, Juszczak E, McInnery K, Derby L (1996) Development of hematopoietic cancers after implantation of total joint replacement. *Clin Orthop Rel Res* **329**: S290-296.
- Girard J, Lavigne M, Vendittoli PA, Roy AG (2006) Biomechanical reconstruction of the hip: a randomised study comparing total hip resurfacing and total hip arthroplasty. *J Bone Joint Surg (Br)* **88**: 721-726.
- Glyn-Jones S, Pandit H, Kwon Y, Doll H, Gill HS, Murray DW (2009) Risk factors for inflammatory pseudotumour formation following hip resurfacing. *J Bone Joint Surg (Br)* **91**: 1566-1574.
- Gore DR, Murray MP, Gardner GM, Sepic SB (1985) Hip function after total v.s. surface replacement. *Acta Orthop* **56**: 386-390.
- Grammatopoulos G, Pandit H, Kwon YM, Gundle R, McLardy-Smith P, Beard DJ, Murray DW, Gill HS (2009) Hip resurfacings revised for inflammatory pseudotumour have a poor outcome. *J Bone Joint Surg (Br)* **91**: 1019-1024.
- Gruber FW, Bock A, Trattng S, Lintner F, Ritschl P (2007) Cystic lesion of the groin due to metallosis: A rare long-term complication of metal-on-metal total hip arthroplasty. *J Arthroplasty* **22**: 923-927.
- Hallab N (2001) Metal sensitivity in patients with orthopaedic implants. *J Bone Joint Surg (Am)* **83**: 428-436.
- Hallab NJ, Vermes C, Messina C, Roebuck KA, Glant TT, Jacobs JJ (2002) Concentration- and composition-dependent effects of metal ions on human MG-63 osteoblasts. *J Biomed Mater Res* **60**: 420-433.
- Hallab NJ, Anderson S, Stafford T, Glant T, Jacobs JJ (2005) Lymphocyte responses in patients with total hip arthroplasty. *J Orthop Res* **23**: 384-391.
- Hananouchi T, Nishii T, Lee SB, Ohzono K, Yoshikawa H, Sugano N (2010) The vascular network in the femoral head and neck after hip resurfacing. *J Arthroplasty* **25**: 146-151.
- Hart AJ, Scott G (2005) Hip resurfacing following previous proximal femoral osteotomy. *Hip Int* **15**: 119-122.
- Hart AJ, Hester T, Sinclair K, Powell JJ, Goodship AE, Pele L, Fersht NL, Skinner J (2006) The association between metal ions from hip resurfacing and reduced T-cell counts. *J Bone Joint Surg (Br)* **88**: 449-454.
- Hart AJ, Sabah S, Henckel J, Lewis A, Cobb J, Sampson B, Mitchell A, Skinner JA (2009) The painful metal-on-metal hip resurfacing. *J Bone Joint Surg (Br)* **91**: 738-744.
- Head WC (1951) Wagner surface replacement arthroplasty of the hip. Analysis of fourteen failures in forty-one hips. *J Bone Joint Surg (Am)* **63**: 420-427.
- Herrlin K, Pettersson H, Selvik G, Lidgren L (1988) Femoral anteversion and restricted range of motion in total hip prostheses. *Acta Radiol* **29**: 551-553.
- Hing CB, Back DL, Bailey M, Young DA, Dalziel RE, Shimmin AJ, Lidgren L (2007) The results of primary Birmingham hip resurfacings at a mean of five years: an independent prospective review of the first 230 hips. *J Bone Joint Surg (Br)* **89**: 1431-1438.
- Howie DW, Campbell D, McGee M, Cornish BL (1990) Wagner resurfacing arthroplasty: the results of one hundred consecutive arthroplasties after eight to ten years. *J Bone Joint Surg (Am)* **72**: 708-714.
- Howie DW, Cornish BL, Vernon-Roberts B (1993) The viability of the femoral head after resurfacing hip arthroplasty in humans. *Clin Orthop Rel Res* **291**: 171-184.
- Incavo SJ, Thompson MT, Gold JE, Patel RV, Icenogle KD, Noble PC (2010) Which procedure better restores intact hip range of motion: total hip arthroplasty or resurfacing? A combined cadaveric and computer simulation study. *J Arthroplasty* epub ahead 2010.
- Jacobs MA, Goytia RN, Tarun Bhargava (2008) Hip resurfacing through an anterolateral approach. *J Bone Joint Surg (Am)* **90**: 38-44.
- Jakobsen SS, Danscher G, Stoltenberg M, Larsen A, Bruun JM, Mygind T, Kemp K, Søballe K (2007) Cobalt-chromium-molybdenum alloy causes metal accumulation and metallothionein up-regulation in rat liver and kidney. *Basic Clin Pharmacol Toxicol* **101**: 441-446.
- Jeffers JR, Roques A, Taylor A, Tuke MA (2009) The problem with large diameter metal-on-metal acetabular cup inclination. *Bull NYU Hosp Jt Dis*, **67**: 189-192.
- Jolley MN, Salvati EA, Brown GC (1982) Early results and complications of surface replacement of the hip. *J Bone Joint Surg (Am)* **64**: 366-377.
- Kalhor M, Beck M, Huff TW, Ganz R (2009) Capsular and pericapsular contributions to acetabular and femoral head perfusion. *J Bone Joint Surg (Am)* **91**: 409-418.
- Keegan GM, Learmonth ID, Case CP (2007) Orthopaedic metals and their potential toxicity in the arthroplasty patient: A review of current knowledge and future strategies. *J Bone Joint Surg (Br)* **89**: 567-573.
- Khan A, Yates P, Lovering A, Bannister GC, Spencer RF (2007) The effect of surgical approach on blood flow to the femoral head during resurfacing. *J Bone Joint Surg (Br)* **89**: 21-25.
- Khanduja A, Villar RN (2008) The role of arthroscopy in resurfacing arthroplasty of the hip. *Arthroscopy* **24**: 122.e1-e3.
- Kishida Y, Sugano N, Nishii T, Miki H, Yamaguchi K, Yoshikawa H (2004) Preservation of the bone mineral density of the femur after surface replacement of the hip. *J Bone Joint Surg (Br)* **86**: 185-189.
- Kluess D, Zietz C, Lindner T, Mittelmeier W, Schmitz KP, Bader R (2008) Limited range of motion of hip resurfacing arthroplasty due to unfavorable ratio of prosthetic head size and femoral neck diameter. *Acta Orthop* **79**: 748-754.
- Korovessis P, Petsinis G, Repanti M, Repantis T (2006) Metallosis after contemporary metal-on-metal total hip arthroplasty. Five to nine-year follow-up. *J Bone Joint Surg (Am)* **88**: 1183-1191.
- Kudo O, Sabokbar A, Pocock A, Itonaga I, Fujikawa Y, Athanasou NA (2003) Interleukin-6 and interleukin-11 support human osteoclast formation by a RANKL-independent mechanism. *Bone* **32**: 1-7.

- Ladon D, Doherty A, Newson R, Turner J, Bhamra M, Case CP (2004) Changes in metal levels and chromosome aberrations in the peripheral blood of patients after metal-on-metal hip arthroplasty. *J Arthroplasty* **19**: 78-83.
- Langton DJ, Jameson SS, Joyce TJ, Webb J, Nargol AV (2008) The effect of component size and orientation on the concentrations of metal ions after resurfacing arthroplasty of the hip. *J Bone Joint Surg (Br)* **90**: 1143-1151.
- Lavigne M, Masse V, Roy A, Vendittoli PA. (2008a) Return to sports after hip resurfacing and total hip arthroplasty: a randomized clinical trial. Proceedings AAOS, San Francisco, CA.
- Lavigne M, Rama KR, Roy A, Vendittoli PA (2008b) Painful impingement of the hip joint after total hip resurfacing: a report of two cases. *J Arthroplasty* **23**: 1074-1079.
- Leunig M. (2010) Personal communication, unpublished data.
- Le Duff M, Amstutz H, Dorey F (2007) Metal-on-metal hip resurfacing for obese patients. *J Bone Joint Surg (Am)* **89**: 2705-2711.
- Lidgren L (2008) Chronic inflammation, joint replacement and malignant lymphoma. *J Bone Joint Surg (Br)* **90**: 7-10.
- Lilikakis AK, Arora A, Villar RN (2005) Early rehabilitation comparing hip resurfacing and total hip replacement. *Hip Int* **15**: 189-194.
- Lin ZM, Meakins S, Morlock MM, Parsons P, Hardaker C, Flett M, Isaac G (2006) Deformation of press-fitted metallic resurfacing cups, Part I: experimental simulation. *Proc Inst Mech Eng [H]* **220**: 299-309.
- Liu F, Jin Z, Roberts P, Grigoris P (2006) Importance of head diameter, clearance, and cup wall thickness in elasto-hydrodynamic lubrication analysis of metal-on-metal hip resurfacing prostheses. *Proc Inst Mech Eng [H]* **220**: 695-704.
- Long JP, Bartel DL (2006) Surgical variables affect the mechanics of a hip resurfacing system. *Clin Orthop Rel Res* **453**: 115-122.
- Loughead JM, Starks I, Chesney D, Matthews JN, McCaskie AW, Holland JP (2006) Removal of acetabular bone in resurfacing arthroplasty of the hip: a comparison with hybrid total hip arthroplasty. *J Bone Joint Surg (Br)* **88**: 31-34.
- Macdonald SJ, McCalden RW, Chess DG, Bourne RB, Rorabeck CH, Cleland D, Leung F (2003) Metal-on-metal versus polyethylene in hip arthroplasty: a randomized clinical trial. *Clin Orthop Rel Res* **406**: 282-296.
- Madhu TS, Akula MR, Raman RN, Sharma HK, Johnson VG (2010) The Birmingham hip resurfacing prosthesis. *J Arthroplasty* epub ahead 2010.
- Malik A, Maheshwari A, Dorr LD (2007) Impingement with total hip replacement. *J Bone Joint Surg (Am)* **89**: 1832-1842.
- Malviya A, Holland JP (2009) Pseudotumours associated with metal-on-metal hip resurfacing: 10-year Newcastle experience. *Acta Orthop Belg* **75**: 477-483.
- Malviya A, Lingard EA, Malik A, Bowman R, Holland JP (2010) Hip flexion after Birmingham hip resurfacing. *J Arthroplasty* **25**: 387-391.
- Marker DR, Seyler TM, Jinnah RH, Delanois RE, Ulrich SD, Mont MA (2007) Femoral neck fractures after metal-on-metal total hip resurfacing: a prospective cohort study. *J Arthroplasty* **22 (Suppl 3)**: S66-71.
- Marnett LJ (1999) Lipid peroxidation-DNA damage by malondialdehyde. *Mutat Res* **424**: 83-95.
- McBryde CW, Shears E, O'Hara JN, Pynsent PB (2008) Metal-on-metal hip resurfacing in developmental dysplasia. *J Bone Joint Surg (Br)* **90**: 708-714.
- McBryde CW, Theivendran K, Thomas AMC, Treacy RBC, Pynsent PB (2010) The influence of head size and sex on the outcome of Birmingham hip resurfacing. *J Bone Joint Surg (Am)* **92**: 105-112.
- McCabe JP, Pellicci PM, Salvati EA (1999) Dislocation following total hip arthroplasty, In: Bono JV, McCarthy JC, Turner RH, Thornhill TS, Bierbaum BE, Salvati EA, Revision total hip arthroplasty, New York, Springer, p. 394.
- McGrory B, Barrack R, Lachiewicz PF, Schmalzried TP, Yates AJ, Watters III WC, Turkelson CM, Wies JL, Andre JS (2010) Modern metal-on-metal hip resurfacing. *J Am Acad Orthop Surg* **18**: 306-314.
- McKay GC, Macnair R, MacDonald C, Grant MH (1996) Interactions of Orthopaedic metals with an immortalized rat osteoblast cell line. *Biomaterials* **17**: 1339-1344.
- McMinn D, Treacy R, Lin K, Pynsent P (1996) Metal on metal surface replacement of the hip, Experience of the McMinn prosthesis. *Clin Orthop Relat Res* **329 (Suppl)**: S89-98.
- Mjoberg B, Pettersson H, Rosenqvist R, Rydholm A (1984) Bone cement, thermal injury and the radiolucent zone. *Acta Orthop* **55**: 597-600.
- Mont MA, LaPorte DM, Mullick T, Silberstein CE, Hungerford DS (1999) Tennis after total hip arthroplasty. *Am J Sports Med* **27**: 60-64.
- Mont MA, Seyler TM, Ulrich SD, Beaulé PE, Boyd HS, Grecula MJ, Goldberg VM, Kennedy WR, Marker DR, Schmalzried TP, Sparling EA, Parker Vail T, Amstutz HC (2007) Effect of changing indications and techniques on total hip resurfacing. *Clin Orthop Relat Res* **465**: 63-70.
- Mont MA, Marker DR, Smith JM, Ulrich SD, McGrath MS (2009) Resurfacing is comparable to total hip arthroplasty at short-term follow-up. *Clin Orthop Relat Res* **467**: 66-71.
- Moonot P, Singh PJ, Kalairajah YE, Kavanagh TG, Field RE (2008) Birmingham hip resurfacing: is acetabular bone conserved? *J Bone Joint Surg (Br)* **90**: 319-323.
- Morais S, Carvalho GS, Faria JL, Gomes HT, Sousa JP (1998) *In vitro* biomineralization by osteoblast-like cells. I. Retardation of tissue mineralization by metal salts. *Biomaterials* **19**: 13-21.
- Morlock MM, Bishop N, Zustin J, Hahn M, R  ther W, Amling M (2008) Modes of implant failure after hip resurfacing: morphological and wear analysis of 267 retrieval specimens. *J Bone Joint Surg (Am)* **90 (Suppl 3)**: S89-95.
- Naal FD, Maffiuletti NA, Munzinger U, Hersche O (2007) Sports after hip resurfacing arthroplasty. *Am J Sports Med* **35**: 705-711.

- Naal FD, Kain MS, Hersche O, Munzinger U, Leunig M (2009) Does hip resurfacing require larger acetabular cups than conventional THA? *Clin Orthop Relat Res* **467**: 923-928.
- Narvani AA, Tsiroidis E, Nwaboku HCI, Bajekal RA (2006) Sporting activity following Birmingham hip resurfacing. *Int J Sports Med* **27**: 505-507.
- Nasser AB, Beaulé PE, O'Neill M, Kim PR, Fazekas A (2010) Incidence of groin pain after metal-on-metal hip resurfacing. *Clin Orthop Relat Res* **468**: 392-399.
- Nikolaou V, Bergeron SG, Huk OL, Zukor DJ, Antoniou J (2009) Evaluation of persistent pain after hip resurfacing. *Bull NYU Hosp Jt Dis* **67**: 168-172.
- Nork SE, Schar M, Pfander G, Beck M, Djonov V, Ganz R, Leunig M (2005) Anatomic considerations for the choice of surgical approach for hip resurfacing arthroplasty. *Orthop Clin North Am* **36**: 163-170.
- O'Sullivan M, Tai CC, Richards S, Skyrme AD, Walter WL, Walter WK (2007) Iliopsoas Tendinitis, A complication after total hip arthroplasty. *J Arthroplasty* **22**: 166-170.
- Ollivere B, Darrah C, Barker T, Nolan J, Porteous MJ (2009) Early clinical failure of the Birmingham metal-on-metal hip resurfacing is associated with metallosis and soft-tissue necrosis. *J Bone Joint Surg (Br)* **91**: 1025-1030.
- Ong KL, Day JS, Kurtz SM, Field RE, Manley MT (2008) Role of surgical position on interface stress and initial bone remodelling stimulus around hip resurfacing arthroplasty. *J Arthroplasty* **24**: 1137-1142.
- Pandit H, Glyn-Jones S, McLardy-Smith P, Gundle R, Whitwell D, Gibbons CL, Ostlere S, Athanasou N, Gill HS, Murray DW (2008) Pseudotumours associated with metal-on-metal hip resurfacings. *J Bone Joint Surg (Br)* **90**: 847-851.
- Papageorgiou I, Brown C, Schins R, Singh S, Newson R, Davis S, Fisher J, Ingham E, Case CP (2007) The effect of nano- and micron-sized particles of cobalt-chromium alloy on human fibroblasts *in vitro*. *Biomaterials* **28**: 2946-2958.
- Park YS, Moon YW, Lim SJ, Yang JM, Ahn G, Choi YL (2005) Early osteolysis following second-generation metal-on-metal hip replacement. *J Bone Joint Surg (Am)* **87**: 1515-1521.
- Pollard TC, Baker RP, Eastaugh-Waring SJ, Bannister GC (2006) Treatment of the young active patient with osteoarthritis of the hip. A five- to seven-year comparison of hybrid total hip arthroplasty and metal-on-metal resurfacing. *J Bone Joint Surg (Br)* **5**: 592-600.
- Prosser GH, Yates PJ, Wood DJ, Graves SE, de Steiger RN, Miller LN (2010) Outcome of primary resurfacing hip replacement: evaluation of risk factors for early revision. *Acta Orthop* **81**: 66-71.
- Radcliffe IA, Taylor M (2007) Investigation into the effect of varus-valgus orientation on load transfer in the resurfaced femoral head: a multi-femur finite element analysis. *Clin Biomech (Bristol, Avon)* **22**: 780-786.
- Rae T (1986) The macrophage response to implant materials. *Crit Rev Biocompatibility* **2**: 97-126.
- Scheerlinck T, Delpont H, Kiewitt T (2010) Influence of the cementing technique on the cement mantle in hip resurfacing. *J Bone Joint Surg (Am)* **92**: 375-387.
- Schmalzried TP, Buttman D, Grecula M, Amstutz HC (1994) The relationship between the design, position, and articular wear of acetabular components inserted without cement and the development of pelvic osteolysis. *J Bone Joint Surg (Am)* **76**: 677-688.
- Schmalzried TP, Noordin S, Amstutz HC (1997) Update on nerve palsy associated with total hip replacement. *Clin Orthop Relat Res* **344**: 188-206.
- Schmalzried TP, Silva M, de la Rosa MA, Choi ES, Fowble VA (2005) Optimizing patients selection and outcomes with total hip resurfacing. *Clin Orthop Rel Res* **441**: 200-204.
- Schoeniger R, Espinosa N, Sierra RJ, Leunig M, Ganz R (2009a) Role of the extra-osseous blood supply in osteoarthritic femoral heads. *Clin Orthop Rel Res* **467**: 2235-2240.
- Schoeniger R, LaFrance AE, Oxland TR, Ganz R, Leunig M (2009b) Does trochanteric step osteotomy provide greater stability than classic slide osteotomy. A preliminary study. *Clin Orthop Relat Res* **467**: 775-782.
- Seki M, Yuasa N, Ohkuni K (1998) Analysis of optimal range of socket orientations in total hip arthroplasty with use of computer-aided design simulation. *J Orthop Res* **16**: 513-517.
- Seyler TM, Lai LP, Sprinkle DI, Ward WG, Jinnah RH (2008) Does computer-assisted surgery improve accuracy and decrease the learning curve in hip resurfacing. A radiographic analysis. *J Bone Joint Surg (Am)* **90**: 71-80.
- Shimmin AJ, Back D (2005) Femoral neck fractures following Birmingham hip resurfacing: a national review of 50 cases. *J Bone Joint Surg (Br)* **87**: 463-464.
- Shimmin AJ, Bare J, Back DL (2005) Complications associated with hip resurfacing arthroplasty. *Orthop Clin North Am* **36**: 187-193.
- Shimmin A, Beaulé PE, Campbell P (2008) Metal-on-metal hip resurfacing arthroplasty. *J Bone Joint Surg (Am)* **90**: 637-654.
- Shimmin AJ, Walter WL, Esposito C (2010) The influence of the size of the component on the outcome of resurfacing arthroplasty of the hip. *J Bone Joint Surg (Br)* **92**: 469-472.
- Siebel T, Maubach S, Morlock MM (2006) Lessons learned from early clinical experience and results of 300 ASR hip resurfacing implantations. *Proc Inst Mech Eng [H]* **220**: 345-353.
- Sieber HP, Rieker CB, Köttig P (1999) Analysis of 118 second-generation metal-on-metal retrieved hip implants. *J Bone Joint Surg (Br)* **81**: 46-50.
- Smith SL, Dowson D, Goldsmith AA (2001) The effect of femoral head diameter upon lubrication and wear of metal-on-metal total hip replacements. *Proc Inst Mech Eng [H]* **215**: 161-170.
- Steffen RT, Smith SR, Urban JP, McLardy-Smith P, Beard DJ, Gill HS, Murray DW (2005) The effect of hip resurfacing on oxygen concentration in the femoral head. *J Bone Joint Surg (Br)* **87**: 1468-1474.
- Steffen RT, Pandit HP, Palan J, Beard DJ, Gundle R, McLardy-Smith P, Murray DW, Gill HS (2008) The five year results of the Birmingham hip resurfacing arthroplasty. *J Bone Joint Surg (Br)* **90**: 436-441.

- Steffen RT, Fern D, Norton M, Murray DW, Gill HS (2009a) Femoral oxygenation during hip resurfacing through the trochanteric flip approach. *Clin Orthop Relat Res* **467**: 934-939.
- Steffen RT, Foguet PR, Krikler SJ, Gundle R, Beard DJ, Murray DW (2009b) Femoral neck fractures after hip resurfacing. *J Arthroplasty* **24**: 614-619.
- Steffen RT, De Smet KA, Murray DW, Singh H (2010) A modified posterior approach preserves femoral head oxygenation during hip resurfacing. *J Arthroplasty* epub ahead 2010.
- Taher RT, Power RA (2003) Iliopsoas tendon dysfunction as a cause of pain after total hip arthroplasty relieved by surgical release. *J Arthroplasty* **18**: 387-388.
- Taylor M (2006) Finite element analysis of the resurfaced femoral head. *Proc Inst Mech Eng [H]* **220**: 289-297.
- Treacy RB, McBryde CW, Pynsent PB (2005) Birmingham hip resurfacing arthroplasty. A minimum follow-up of five years. *J Bone Joint Surg (Br)* **87**: 167-170.
- Vail TP, Mina CA, Yergler JD, Pietrobon R (2006) Metal-on-metal hip resurfacing compares favorably with THA at 2 years follow-up. *Clin Orthop Relat Res* **453**: 123-131.
- Vendittoli PA, Lavigne M, Girard J, Roy AG (2006) A randomised study comparing resection of acetabular bone at resurfacing and total hip replacement. *J Bone Joint Surg (Br)* **88**: 997-1002.
- Vendittoli PA, Mottard S, Roy AG, Dupont C, Lavigne M (2007) Chromium and cobalt ion release following the Durom high carbon content, forged metal-on-metal surface replacement of the hip. *J Bone Joint Surg (Br)* **89**: 441-448.
- von Schewelov T, Sanzén L (2010) Catastrophic failure due to aggressive metallosis 4 years after hip resurfacing in a woman in her forties - a case report. *Acta Orthop* **81**: 402-404.
- Walker PS, Soudry M, Ewald FC, McVickar H (1984) Control of cement penetration in total knee arthroplasty. *Clin Orthop Relat Res* **185**: 155-164.
- Whiteside LA, Lange DR, Capello WR, Fraser B (1983) The effects of surgical procedures on the blood supply to the femoral head. *J Bone Joint Surg (Am)* **65**: 1127-1133.
- Willert HG, Buchhorn GH, Fayyazi A, Flury R, Windler M, Koster G, Lohmann CH (2005) Metal-on-metal bearings and hypersensitivity in patients with artificial hip joints. A clinical histomorphological study. *J Bone Joint Surg (Am)* **87**: 28-36.
- Witkiewicz-Kucharczyk A, Bal W (2006) Damage of zinc fingers in DNA repair proteins, a novel molecular mechanism in carcinogenesis. *Toxicol Lett* **162**: 29-42.
- Witzleb WC, Hanisch U, Kolar N, Krummenauer F, Guenther KP (2007) Neo-capsule tissue reactions in metal-on-metal hip arthroplasty. *Acta Orthop* **78**: 211-220.
- Wolf T, Kasemann R, Ottenwalder H (1989) Molecular interaction of different chromium species with nucleotides and nucleic acids. *Carcinogenesis* **10**: 655-659.
- Wylde V, Blom A, Dieppe P, Hewlett S, Learmonth I (2008) Return to sport after joint replacement. *J Bone Joint Surg (Br)* **90**: 920-923.
- Ziaee H, Daniel J, Datta AK, Blunt S, McMinn DJ (2007) Transplacental transfer of cobalt and chromium in patients with metal-on-metal hip arthroplasty: a controlled study. *J Bone Joint Surg (Br)* **89**: 301-305.
- Zustin J, Krause M, Breer S, Hahn M, von Domarus C, Ruther W, Sauter G, Morlock MM, Amling M (2010) Morphologic analysis of periprosthetic fractures after hip resurfacing arthroplasty. *J Bone Joint Surg (Am)* **92**: 404-410.
- Zywieli MG, Marker DR, McGrath MS, Delanois RE, Mont MM (2009) Resurfacing matched to standard total hip arthroplasty by preoperative activity levels. *Bull NYU HospJoint Dis* **67**: 116-119.

Web References

- Web ref.1.** National Joint Registry for England and Wales, Fourth Annual Report, Available at: www.njrcentre.org.uk. Accessed January 6, 2009. (28out10).
- Web ref. 2.** Swedish Hip Arthroplasty Register Annual Report 2006. Available at: www.jru.orthop.gu.se. Accessed January 6, 2009. (38out10).
- Web ref. 3.** Swedish Hip Arthroplasty Register Annual Report 2007. Available at: www.jru.orthop.gu.se. Accessed January 6, 2009. (39out10).
- Web ref. 4.** Australian Orthopaedic Association. National Joint Replacement Registry Annual Report 2008. Available at: www.dmac.adelaide.edu.au/aoanjrr/. Accessed January 6, 2009. (5out10).